Scientific Research Publishing

Open Journal of Urology, 2026, 16(11), 573-578
https://www.scirp.org/journal/oju
ISSN Online: 2160-5629
ISSN Print: 2160-5440

Paraurethral Cyst in Burkina Faso: A Case Report

Aïssata Ouédraogo[1*], Tieoulé Mamadou Traoré[1], Pazoudba Rachida Marie Josephine Ouédraogo/Drabo[1], Youmandia Prosper Komberé[1], Fasnéwindé Aristide Kabore[2]

[1]Department of Surgery, Faculty of Medicine of Ledéa Bernard Ouedraogo University, Urology Service of CHUR of Ouahigouya, Ouahigouya, Burkina Faso
[2]Department of Surgery, Faculty of Medicine of Joseph Ki ZERBO, Urology Service of CHUR of Ouagadougou, Ouagadougou, Burkina Faso
Email: *aurelianaelle09@gmail.com

How to cite this paper: Ouédraogo, A., Traoré, T.M., Ouédraogo/Drabo, P.R.M.J., Komberé, Y.P. and Kabore, F.A. (2026) Paraurethral Cyst in Burkina Faso: A Case Report. *Open Journal of Urology*, **16**, 573-578.
https://doi.org/10.4236/oju.2026.1611058

Received: September 22, 2026
Accepted: November 21, 2026
Published: November 24, 2026

Copyright © 2026 by author(s) and Scientific Research Publishing Inc.
This work is licensed under the Creative Commons Attribution International License (CC BY 4.0).
http://creativecommons.org/licenses/by/4.0/

Open Access

Abstract

Paraurethral cyst is an uncommon pathology of the female lower urinary tract. It may remain asymptomatic or present with bothersome symptoms such as dysuria, recurrent urinary tract infections, or local discomfort. We report the rare case of a young virgin woman presenting with a symptomatic paraurethral cyst, revealed by voiding difficulties. Surgical management was performed, consisting of complete cystectomy associated with hymeneal repair, which preserved anatomical integrity and functional outcomes. Postoperative evolution was favorable, with resolution of symptoms and no recurrence observed. This case highlights the importance of early diagnosis and tailored surgical.

Keywords

Paraurethral Cyst, Uncommon, Complete Cystectomy, Burkina Faso

1. Introduction

Paraurethral cyst is a rare pathology. The clinical symptomatology related to paraurethral cyst is variable. It is most often asymptomatic, of fortuitous discovery during a gynaecological or urological examination. When the cyst is symptomatic, its mode of revelation may be recurrent urinary tract infections, associated or not with symptoms of the emptying and filling phase. In Burkina Faso, after a review of the literature, no publication was found concerning this pathology. Its management may be based on simple monitoring or surgical treatment.

2. Observation

It was an 18-year-old patient, a resident student in Ouagadougou. She was seen in the urology andrology department of the Yalgado Ouédraogo University Hospital Center for a painful vulvar mass. This mass would have evolved more than a year ago, at first not painful but annoying when getting off the bike and then painful. The patient reported a push effort during urination with deviation of the urinary stream to the right. We did not note any known medical history in this patient. The general clinical examination was normal.

The urological examination, the study of urination showed a frank urinary stream but deflected to the right with straw-yellow urine, without urination burning. At the vulvar level, there was a renitent swelling developed at the level of the anterior vaginal wall on the path of the urethra (Figure 1). It is painful to the touch with a urethral meatus visualized after the mass is pushed back to the left.



Figure 1. Giant paraurethral cyst flush with the vulva. Urethral meatus not visualized. Source: Urology-andrology department of the CHUYO.

The laboratory assessment carried out was normal, namely the complete blood count, the serum creatinine, the cytobacteriological examination of the urine.

Pelvic ultrasound was in favor of a rearranged cyst (Figure 2), and retrograde urethrocystography and urination found a large left anterolateral vaginal cystic mass of 37 × 32 × 12 mm (ultrasound volume estimated at 12 cc) without communication with the urethra, responsible for a mass effect with backflow and lateralization of the urethra to the right on CT scan (Figure 3).

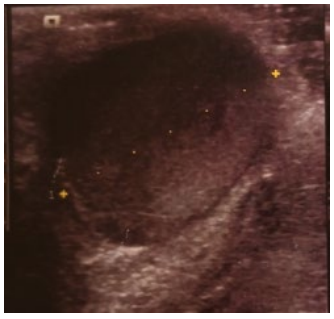

Figure 2. Ultrasound appearance of the paraurethral cyst. Source: Urology-andrology department of the CHUYO.



Figure 3. CT scan of the paraurethral cyst. Source: Urology-andrology department of the CHUYO.

The patient underwent surgical care after her written informed consent was obtained. Her parents were reassured about their daughter's care. A cystectomy and a hymenal repair were performed. After the incision on the anterior vaginal wall of about 4 cm, dissection to split the vaginal mucosa of the cyst and the urethra. The cyst was accidentally opened with aspirated pus for a cytobacteriological study. We washed the cystic cavity before continuing the dissection, doubling and extraction of the cystic shell from the urethra, suturing of the anterior vaginal wall and hymeneal repair (**Figures 4-7**). No histopathological studies have been performed. The urinary catheter is left in place for 2 days. The evolution was favorable. The patient seen again at the first and 6 months postoperatively and had healed well with no pain and no symptoms of the lower urinary tract.

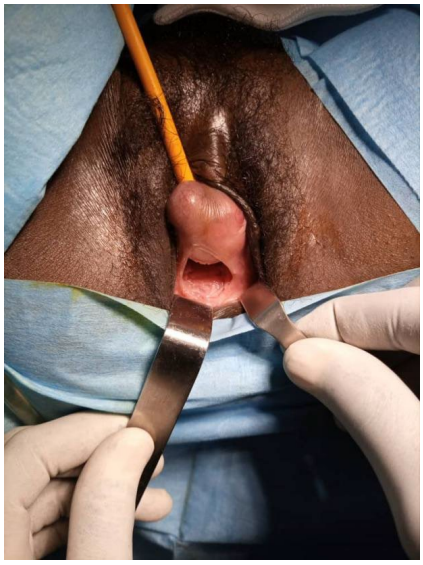

Figure 4. Transurethral bladder catheterization and open the vaginal opening. Source: Urology-andrology department of the CHUYO.

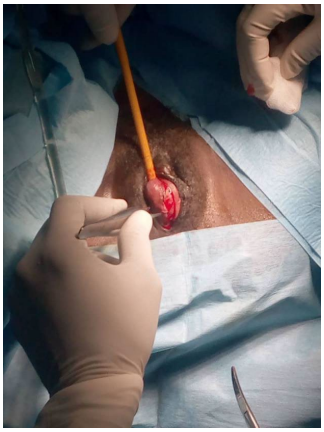

Figure 5. 4 cm incision on the anterior vaginal wall. Source: Urology-andrology department of the CHUYO.

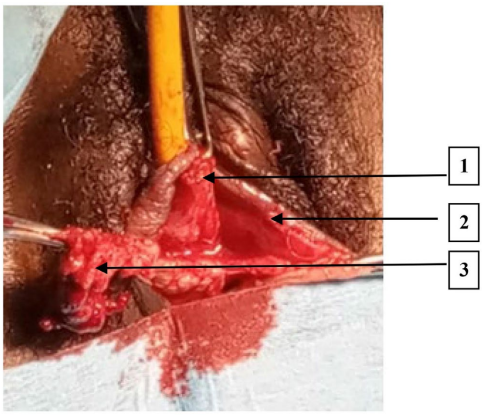

1. Urethra 2. Vagina 3. Cyst shell

Figure 6. Splitting of the anterior vaginal wall of the cyst wall and Splitting of the urethral cyst. Source: Urology-andrology department of the CHUYO.

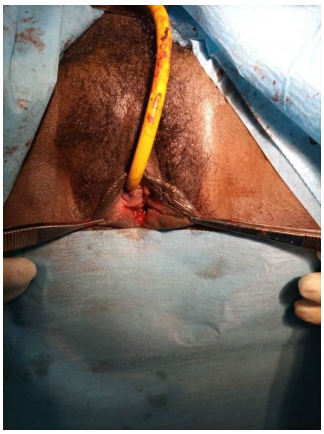

Figure 7. Final aspect (cystectomy, vaginal suture, hymenal reconstruction). Source: Urology-andrology department of the CHUYO.

3. Discussion

Paraurethral cyst is a rare pathology. There are few studies published worldwide.

Its incidence in the female population is in the range of 0.6% to 6% [1]. The lesion occurs in the paraurethral glands, the number of which varies between 6 and 30 [2]. In the English literature, there were only 49 cases and its incidence in children was 1 in 1038 births [3]. In Africa, there are few studies on this pathology. This could be due to the fact that the paraurethral cyst is most often asymptomatic and also that isolated cases are probably not published. In Burkina Faso, no studies concerning this pathology were found after a review of the literature. We found one case and this trend is observed in other studies [1] [2] [4]. The age of discovery of a paraurethral cyst is variable. Clark TJ reported a case discovered during a prenatal ultrasound at 33 weeks of amenorrhea [5]. Fujimoto T [3] reported 5 cases in 5 years in newborns. In our case, the age of diagnosis was 18 years in a virgin patient. The paraurethral cyst can be congenital or acquired. Its pathogenesis remains contraversed and discussed. The most likely hypothesis is that of Routh A, according to which infection and repeated obstruction of the periurethral glands lead to the formation of suburethral cysts [6]. There is a clear predominance of the female sex [1]-[4]. The predominance of paraurethral cysts in women is mainly explained by the existence of Skene's paraurethral glands, whose ductal obstruction can lead to secretion retention and the formation of a cystic lesion. The clinical symptomatology of a paraurethral cyst is non-specific related to the degree of urethral obstruction. Our patient complained of vulvar pain associated with pushing effort and a deviation of the urinary stream. Patients were also symptomatic in the case of Abdallah H and Diabaté I [1] [4]. The reference examination for the diagnosis of paraurethral cyst is pelvic MRI. It allows to characterize the paraurethral mass and especially to differentiate it from a urethral diverticulum. In our case, endovaginal ultrasound and UCRM made it possible to refine the diagnosis with a pelvic CT supplement. The treatment of a para-urethral cyst is not well standardized. It can involve therapeutic abstention, needle aspiration of the cyst, or surgical treatment. In the series by Johnson CT [5] and Takao Fujimoto [3], patients were monitored with spontaneous regression occurring between 2 days and 304 days after birth. Our patient underwent surgical treatment, as in the studies by Kassogué A [4], Hussein A [1], and Epoupa Ngalle F [2]. We obtained her consent as well as her parents' after counseling because she was a virgin. The pain prevented her from riding her bike to school, and the dysuria and aesthetic appearance bothered her deeply. The cyst's content was purulent, and cytobacteriological analysis of the pus did not identify any germ. The urinary catheter was removed 48 hours after the procedure at discharge from the hospital. The outcome was favorable at 1 month and 6 months after the surgery.

4. Conclusion

Female paraurethral cyst is a rare condition that can be difficult to diagnose due to its anatomical proximity to the urethra and vagina. Imaging makes it possible to specify the location and relationships of the lesion and to look for possible communication with the urethra. A complete cystectomy is the standard treatment

when the lesion is symptomatic or large. In our 18-year-old patient, surgical excision was successfully performed, with a favorable postoperative outcome.

Ethics Statement

Written informed consent was obtained from the patient for the publication of this article.

Conflicts of Interest

The authors declare no conflicts of interest regarding the publication of this paper.

References

[1] Hussein, A., Hamza, D., Salim, O., Al Sayegh, H., Lounis, B. and Yassine, N. (2020) KYSTE PARA-URETRAL FEMININ: A PROPOS DUN CAS RARE ET REVUE DE LA LITERATURE. *International Journal of Advanced Research*, **8**, 599-602. https://doi.org/10.21474/ijar01/10816

[2] Epoupa Ngalle, F., Nwaha Makon, A.S., Fouda, J.C., Mbouche, L.O., Mekeme Mekeme, J., Mbassi Mbassi, A.A., *et al.* (2022) Kyste para-urétral symptomatique chronique: À propos de 2 cas. *Revue de Médecine et de Pharmacie*, **12**, 1502-1506. https://www.researchgate.net/publication/373424234

[3] Fujimoto, T., Suwa, T., Ishii, N. and Kabe, K. (2007) Paraurethral Cyst in Female Newborn: Is Surgery Always Advocated? *Journal of Pediatric Surgery*, **42**, 400-403. https://doi.org/10.1016/j.jpedsurg.2006.10.030

[4] Kassogué, A., Coulibaly, M., Ouattara, Z., Diarra, A., Tembely, A., Ouattara, K., *et al.* (2014) Kyste géant para-urétral féminin. *Pan African Medical Journal*, **19**, Article Number 17. https://doi.org/10.11604/pamj.2014.19.17.4299

[5] Johnson, C.T., Millard, S.E., Wang, M. and Ehsanipoor, R.M. (2013) Prenatal Diagnosis of a Paraurethral Cyst. *Journal of Pediatric Urology*, **9**, e91-e93. https://doi.org/10.1016/j.jpurol.2012.10.003

[6] Routh, A. (1890) Urethral Diverticulum. *British Medical Journal*, **1**, 360-365.