Scientific Research Publishing

Open Journal of Radiology, 2026, 16(4), 184-191
https://www.scirp.org/journal/ojrad
ISSN Online: 2164-3032
ISSN Print: 2164-3024

Neonatal Prune Belly Syndrome: Contribution of Medical Imaging, a Case Report

Mongu Serge Boika, Gaela Malembe, Mpungu Alphonsine Nzambi, Ahonzapa Grácia Nguma, Mwakenze Gaetan Matumele, Mukanya Joel Dola, Tanzia Angèle Mbongo, Aundu Antoine Molua

Department of Radiology and Medical Imaging, Kinshasa, Democratic Republic of the Congo
Email: *sergeboikatahrirr@gmail.com

How to cite this paper Boika, M.S., Malembe, G., Nzambi, M.A., Nguma, A.G., Matumele, M.G., Dola, M.J., Mbongo, T.A. and Molua, A.A. (2026) Neonatal Prune Belly Syndrome: Contribution of Medical Imaging, a Case Report. *Open Journal of Radiology*, **16**, 184-191.
https://doi.org/10.4236/ojrad.2026.164019

Received: August 19, 2026
Accepted: November 20, 2026
Published: November 23, 2026

Copyright © 2026 by author(s) and Scientific Research Publishing Inc.
This work is licensed under the Creative Commons Attribution International License (CC BY 4.0).
http://creativecommons.org/licenses/by/4.0/

Open Access

Abstract

Introduction: Prune Belly syndrome is a rare congenital malformation characterized by abdominal muscle weakness, urinary tract anomalies, and bilateral cryptorchidism. Its documentation remains limited in sub-Saharan Africa, particularly in the Democratic Republic of Congo. **Observation:** We report the case of a full-term male newborn, without a documented prenatal diagnosis, admitted for severe abdominal distension with a flaccid and folded abdominal wall, associated with bilateral scrotal emptiness. Ultrasound revealed thin anterior abdominal muscles, bilateral pyelocaliceal dilation with dilation of the proximal ureters, thinning of the renal parenchyma predominantly on the left, and a distended bladder with a thin wall. The testes were not visualized in the scrotal compartments or along the explored inguinal tracts. Thoracoabdominal radiography showed bowel distension with air-fluid levels. Ultrasound also revealed bowel distension, bowel wall thickening without hypervascularity on color Doppler, hypoperistalsis, and inter-loop effusion. The convergence of clinical and radiological data made it possible to conclude a complete Prune Belly syndrome, with bilateral dilated uropathy and renal morphological impact. **Conclusion:** This observation highlights the complementary contribution of conventional radiography and especially ultrasound in the postnatal characterization of Prune Belly syndrome. Imaging allows for early mapping of urological and renal involvement, assessment of its morphological impact, and documentation of associated abdominal manifestations.

Keywords

Prune Belly Syndrome, Ultrasound, Congenital Uropathy, Radiology Department, Kinshasa

1. Introduction

Prune Belly syndrome (PBS), or Eagle-Barrett syndrome, is a rare congenital malformation characterized, in its complete form, by the combination of anterior abdominal muscle weakness, urinary tract anomalies, and bilateral cryptorchidism. Beyond this triad, its clinical presentation is heterogeneous, and its prognosis largely depends on the severity of the urological and renal involvement and associated malformations [1]. Its incidence has been estimated at 3.8 cases per 100,000 live male births, reflecting its rarity [2] [3].

Imaging plays a central role in the assessment of PBS, from prenatal screening to postnatal characterization. In newborns, ultrasound allows for the evaluation of renal morphology and parenchyma, urinary tract dilation, ureters and bladder, and, depending on the clinical context, the exploration can be extended to the abdominal wall and inguinoscrotal regions [1] [2]. Its contribution thus lies less in the isolated identification of the syndrome than in the morphological mapping of the uropathy, its renal impact, and associated anomalies.

In Africa, the scientific documentation remains fragmented. A systematic review identified 58 patients from only 16 publications, without establishing a robust continental incidence [4]. In the Democratic Republic of the Congo, a few observations have been published, including the first at the University Clinics of Kinshasa in 2015 [5]. In this context, we report a new case of Prune Belly syndrome diagnosed in the neonatal period at this institution, in the absence of a documented prenatal diagnosis. The objective is to describe its clinical and radiological characteristics and to illustrate the complementary contribution of conventional radiography and ultrasound in its postnatal morphological characterization.

2. Observation

A male newborn, born at term at 39.5 weeks of gestation via vaginal delivery, with a birth weight of 3605 g, was transferred to the University Clinics of Kinshasa for severe abdominal distension present at birth. The pregnancy had been monitored at a peripheral health facility, without documented obstetric ultrasound. Spontaneous urination was reported, along with delayed meconium passage.

On admission, the abdomen was generally distended, flaccid, and wrinkled, with a thinned abdominal wall exposing the underlying visceral structures. On physical examination, both testes were non-palpable, with bilaterally empty scrotal sacs. The respiratory rate was 70 breaths/minute, with no signs of respiratory distress, and a peripheral oxygen saturation of 96% on room air. Jaundice of the skin and mucous membranes was also present. On day 2 of life, laboratory investigations showed a serum creatinine level of 1.78 mg/dL and a blood urea level of 88.63 mg/dL. Urine output was estimated at 300 mL during the first 24 hours of observation, or approximately 3.5 mL/kg/h.

On day 3 of life, thoracoabdominal radiography and abdominal ultrasound were performed. The frontal thoracoabdominal radiograph showed abdominal distension dominated by a large horizontal air-fluid level in the right hemi-abdo-

men, associated with a few smaller air-fluid levels, without visible pneumoperitoneum (Figure 1).

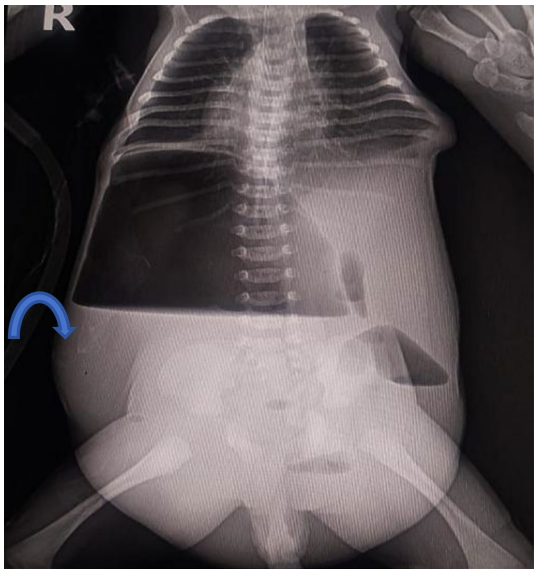

Figure 1. Frontal chest and abdominal radiograph of the newborn on day 3. Overall abdominal distension with a large air-fluid level predominantly in the right hemi-abdomen (blue arrow), including a large horizontal air-fluid level. Several smaller air-fluid levels are present in the lower abdominal region, with bowel stasis.

Abdominal and urogenital ultrasound performed on the same day revealed thin anterior abdominal muscles, measuring approximately 2 mm. The kidneys measured 49 mm on the right and 50 mm on the left, with bipolar axes. Bilateral pyelocaliceal dilation was present, with an anteroposterior diameter of the renal pelvis measuring 8 mm on the right and 10 mm on the left, associated with dilation of the proximal segments of the ureters. The renal parenchyma was thinned, measuring approximately 5 mm on the right and 3 mm on the left. Two rounded, hyperechoic formations measuring 9 mm and 8 mm, without detectable internal vascularization on color Doppler, were identified at the anterior lip of the right kidney. The bladder was distended, with a thin, regular wall of approximately 2 mm. These findings are illustrated in Figure 2, showing bilateral pyelocaliceal dilatation and dilatation of the proximal ureters.

The bowel loops were distended, with wall thickening and no hypervascularity on color Doppler, decreased peristalsis, and anechoic inter-loop effusion. Ultrasound examination showed bilaterally empty scrotal sacs, and no testicular parenchyma was identified along the inguinal tracts examined. The search for an intra-abdominal location was limited by the significant bowel distension and the inter-loop effusion (Figure 3).

The comparison of clinical and radiological findings made it possible to conclude a complete Prune Belly syndrome, combining deficiency of the anterior abdominal musculature, bilateral dilatative uropathy and bilateral cryptorchidism of undetermined location, with renal parenchymal thinning predominantly on the left.

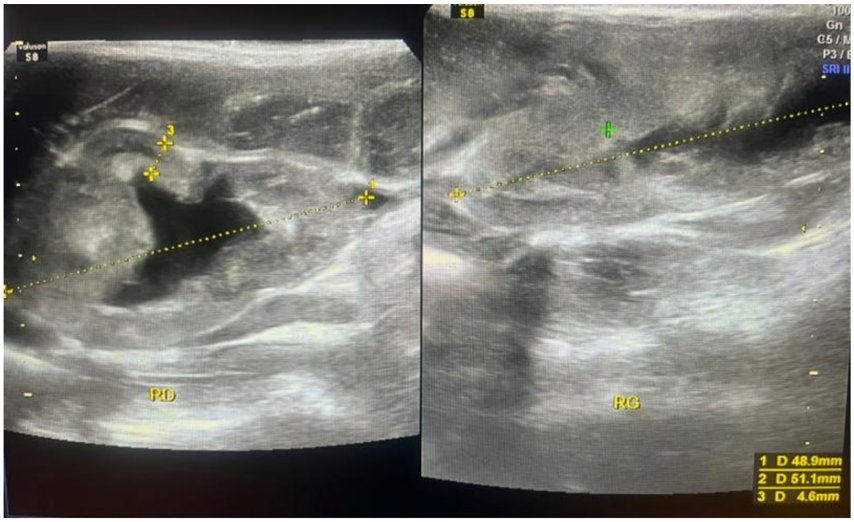

(a)



(b)

Figure 2. Comparative exploration of two kidneys, pyelocaliceal dilation (A) and proximal ureters (B).

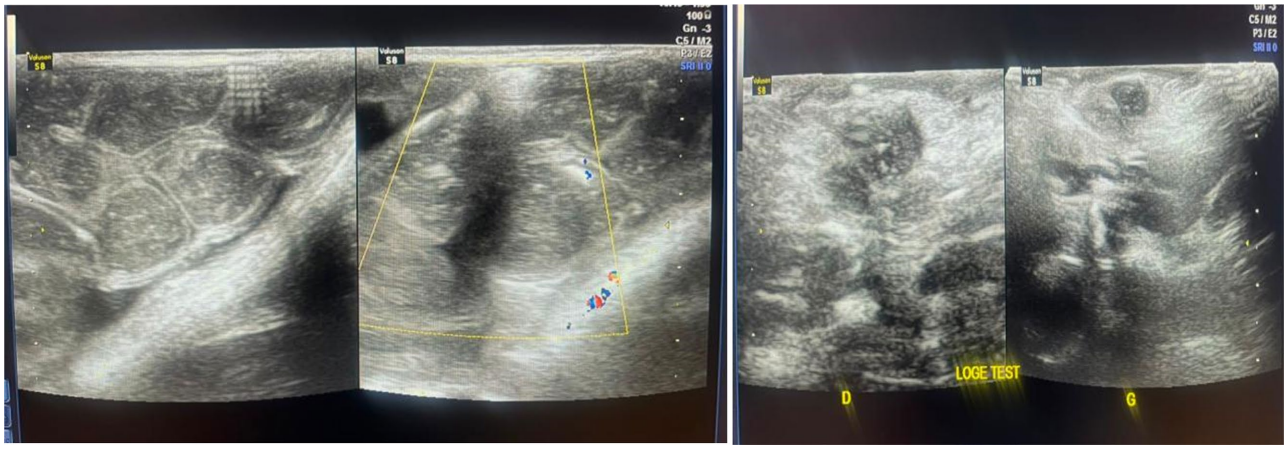

Figure 3. Distension of the digestive loops and emptiness of the testicular compartments.

The newborn was kept hospitalized in the neonatal unit under clinical and laboratory monitoring. Antibiotic therapy with cefotaxime and amikacin, fluid and electrolyte rehydration, and phototherapy were initiated. Nasogastric aspiration yielded approximately 200 mL of dark fluid. A pediatric surgical consultation was subsequently obtained on day 4, and ileus was retained as the gastrointestinal diagnosis. The newborn's clinical condition subsequently deteriorated, and he died on day 5 of life in the pediatric intensive care unit.

3. Discussion

The diagnosis of Prune Belly Syndrome (PBS) in this newborn was based on the presence of all three components of its complete form: anterior abdominal muscle weakness, urinary tract abnormalities, and bilateral cryptorchidism [1] [2]. The marked thinning of the anterior abdominal musculature, measuring approximately 2 mm on ultrasound, correlated with the clinically observed flaccid, distended, and wrinkled abdominal wall. This finding represents one of the major morphological features of PBS and contributes, together with the associated urinary and genital abnormalities, to the postnatal recognition of the syndrome. In our patient, ultrasound therefore provided direct morphological evidence of abdominal wall muscle deficiency and complemented the characteristic findings identified on physical examination.

Uro-renal involvement is a major determinant of the severity of PBS and can include hydroureteronephrosis, bladder abnormalities, and variable renal parenchymal involvement [1] [2]. In our patient, the renal pelvis measured 8 mm on the right and 10 mm on the left, with dilation of the proximal ureters, bladder distension, and parenchymal thinning predominantly on the left. These findings defined bilateral dilatative uropathy without specifying the mechanism. Indeed, PBS is characterized by urinary dilation that can be associated with ureterovesical functional abnormalities; the extent of morphological dilation is therefore insufficient to establish mechanical obstruction [1] [2]. Ultrasound did not confirm vesicoureteral reflux or directly assess bladder emptying dynamics.

Parenchymal thinning also had to be distinguished from unproven renal dysplasia. The initial serum creatinine level of 1.78 mg/dL and the serum urea level of 88.63 mg/dL required an evolving interpretation, particularly in light of preserved diuresis of approximately 3.5 mL/kg/h. Ultrasound thus provides information on parenchymal tissue and the extent of dilation, but cannot, on its own, determine renal function or prognosis. This distinction between morphology, urodynamic mechanism, and renal function is crucial in the interpretation of the PBS [1] [2].

Bilateral cryptorchidism completed the triad. No testes were identified in the scrotal sacs or along the explored inguinal tracts, while bowel distension limited their abdominal search. Tasian and Copp, in a meta-analysis of 12 studies involving 591 non-palpable testes, reported a sensitivity of 45% and a specificity of 78% for ultrasound to locate them [6]. Since the absence of testes on ultrasound does

not allow for confirmation of testicular absence or intra-abdominal location, the formulation of bilateral cryptorchidism with undetermined location appears to be the most accurate.

Gastrointestinal manifestations were another distinctive feature of the observation. Radiography showed air-fluid distension, while ultrasound revealed intestinal distension, parietal thickening without hypervascularization, hypoperistalsis, and inter-loop effusion. Gastrointestinal abnormalities are described in Prune Belly syndrome [1] [2]; however, the gastrointestinal findings observed in our patient were nonspecific. Their association with delayed meconium passage and subsequent aspiration of dark digestive fluid confirmed their clinical relevance without allowing for a definitive diagnosis of mechanical obstruction, malrotation, or volvulus. A pediatric surgical evaluation subsequently retained ileus as the gastrointestinal diagnosis. Similarly, the two avascular hyperechoic formations in the right kidney remained of indeterminate nature, without sufficient ultrasound evidence for histological classification.

African literature remains sparse. Keet *et al.* identified 58 patients in 16 African publications; abdominal muscle weakness was reported in all patients and bilateral cryptorchidism in 96% of male subjects, while bilateral hydroureters and hydronephroses were frequent [4]. Our observation therefore falls within the morphological spectrum described on the continent, while simultaneously documenting the parietal, urorenal, bladder, genital, and digestive compartments.

In the Democratic Republic of the Congo, three published observations preceded our case. Aloni *et al.* described a newborn at the University Clinics of Kinshasa in 2015 presenting with the triad of bilateral hydronephrosis, ureteral dilation, and urachal anomaly [5]. In Lubao, Kabemba Bukasa *et al.* reported a premature newborn in 2022 with abdominal muscle hypoplasia, bilateral cryptorchidism, and left clubfoot [7]. A third observation was published in Kihumba in 2024, focusing more on the clinical and therapeutic features [8]. Our case, therefore, does not claim national primacy; its interest lies in the integrated postnatal radiological characterization of a new case at the University Clinics of Kinshasa, in the absence of a documented prenatal diagnosis.

The contribution of imaging lies in the anatomical delimitation of the phenotype rather than in the extrapolation of its findings. Ultrasound characterizes the uropathy, renal parenchyma, bladder, and abdominal wall, and identifies associated abnormalities; radiography completes the analysis of the digestive impact. However, these modalities alone cannot establish the mechanism of urinary dilation, renal function, the location of non-palpable testes, or the histological nature of the renal lesions. This distinction between demonstrated morphological characterization and unestablished functional interpretation constitutes the main radiological lesson of this case.

4. Conclusion

In this newborn with no documented prenatal diagnosis, ultrasound, supplemented

by thoracoabdominal radiography, allowed for postnatal mapping of the parietal, urogenital, bladder, and digestive involvement associated with Prune Belly syndrome. The value of imaging lies in this early and multicompartmental anatomical characterization, while also distinguishing morphologically demonstrated abnormalities from functional mechanisms, which imaging alone cannot establish.

Consent for Publication

Written informed consent was obtained from the newborn's mother for the publication of the clinical information and accompanying images.

Author Contributions

Conceptualization, Boika M.S., Matumele M.G., and Nzambi M.A.; methodology, Boika M.S.; software, Boika M.S. and Malembe G.; validation, Boika M.S. and Mbongo T.A.; formal analysis, Boika M.S.; investigation, Malembe G., Matumele M.G., Nzambi M.A., and Boika M.S.; resources, Boika M.S., Matumele M.G., Nzambi M.A., and Malembe G.; data curation, Dola M.J., Nguma A.G., and Boika M.S.; writing—original draft preparation, Boika M.S. and Molua A.A.; writing—review and editing, Molua A.A., Mbongo T.A., and Boika M.S.; visualization, Boika M.S.; supervision, Molua A.A. and Mbongo T.A.; project administration, Boika M.S.; funding acquisition, Boika M.S., Molua A.A., Mbongo T.A., Nzambi M.A., Matumele M.G., and Dola M.J. All authors have read and agreed to the published version of the manuscript.

Conflicts of Interest

The authors declare no conflicts of interest regarding the publication of this paper.

References

[1] Arlen, A.M., Nawaf, C. and Kirsch, A.J. (2019) Plum Belly Syndrome: Current Perspectives. *Pediatric Health, Medicine and Therapeutics*, **10**, 75-81. https://doi.org/10.2147/phmt.s188014

[2] Lopes, R.I., Baker, L.A. and Dénes, F.T. (2021) Modern Management of and Update on Prune Belly Syndrome. *Journal of Pediatric Urology*, **17**, 548-554. https://doi.org/10.1016/j.jpurol.2021.04.010

[3] Routh, J.C., Huang, L., Retik, A.B. and Nelson, C.P. (2010) Contemporary Epidemiology and Characterization of Newborn Males with Prune Belly Syndrome. *Urology*, **76**, 44-48. https://doi.org/10.1016/j.urology.2009.12.072

[4] Keet, K., Henry, B.M. and Tubbs, R.S. (2021) Prune-Belly Syndrome in Africa: An Analysis and Systematic Review of Cases, Etiology, Treatment, and Outcomes. *Journal of Clinical Urology*, **14**, 369-384. https://doi.org/10.1177/2051415820903196

[5] Aloni, M.N., Mujinga, V., Tady, B.M. and Nkidiaka, E.D. (2015) A First Description of Prune Belly Syndrome in Central Africa. *Pediatrics & Neonatology*, **56**, 355-356. https://doi.org/10.1016/j.pedneo.2015.01.006

[6] Tasian, G.E. and Copp, H.L. (2011) Diagnostic Performance of Ultrasound in Nonpalpable Cryptorchidism: A Systematic Review and Meta-Analysis. *Pediatrics*, **127**, 119-128. https://doi.org/10.1542/peds.2010-1800

[7] Kabemba Bukasa, H., Ngoyi Kabondo, D., Kitengie Kapafule, S., Mako Kunda, M., Ngoyi Ngoyi Kampule, J., Mudimbi, N., *et al.* (2022) Syndrome de Prune-Belly: A Propos d'un Cas Enregistre a Lubao, République Démocratique du Congo, et Revue de la Litterature. *Tanganyika Journal of Science*, **2**, 49-54. https://doi.org/10.59296/tgjs.2221036

[8] Akili Manegabe, C. and Ciza Badesire, J. (2024) Prune Belly Syndrome: Case of a New Born and Followed at the Kihumba Hospital Center, Special Features on Our Case and Management of Complications. *Archive of Obstetrics, Gynecology and Reproductive Medicine*, **7**, 271-275.