Scientific Research Publishing

Open Journal of Pathology, 2027, 17(1), 1-18
https://www.scirp.org/journal/ojpathology
ISSN Online: 2164-6783
ISSN Print: 2164-6775

Exploratory Associations of Histopathological Features, Direct Immunofluorescence and the Systemic Manifestations in the Case of Histologically Confirmed Cutaneous Leukocytoclastic Vasculitis

Chutika Srisuttiyakorn, Sirada Srithanetsakul

Division of Dermatology, Department of Internal Medicine, Phramongkutklao Hospital, Bangkok, Thailand
Email: schuti101@gmail.com

How to cite this paper: Srisuttiyakorn, C. and Srithanetsakul, S. (2027) Exploratory Associations of Histopathological Features, Direct Immunofluorescence and the Systemic Manifestations in the Case of Histologically Confirmed Cutaneous Leukocytoclastic Vasculitis. *Open Journal of Pathology*, **17**, 1-18.
https://doi.org/10.4236/ojpathology.2027.171001

Received: October 16, 2026
Accepted: November 22, 2026
Published: November 25, 2026

Copyright © 2027 by author(s) and Scientific Research Publishing Inc.
This work is licensed under the Creative Commons Attribution International License (CC BY 4.0).
http://creativecommons.org/licenses/by/4.0/

Open Access

Abstract

Background: Cutaneous leukocytoclastic vasculitis (LCV) is a small-vessel vasculitis that primarily affects postcapillary venules in the skin. Although LCV is typically self-limiting, systemic involvement develops in some patients. While histopathological evaluation and direct immunofluorescence (DIF) can aid in diagnosis and risk stratification, their prognostic value remains largely underexplored. **Objective:** To explore the associations between histopathologic features, direct immunofluorescence findings, and systemic manifestations in patients with a histologic diagnosis of leukocytoclastic vasculitis. **Methods:** This retrospective cohort study was conducted at the Division of Dermatology, Phramongkutklao Hospital, between 2013 and 2024. Forty cases met the inclusion criteria. Medical history, clinical manifestations, histopathological features, and DIF results were analyzed. **Results:** Direct immunofluorescence (DIF) was positive in 29 of 40 cases (72.5%), with C3 and IgM being the two most common immunoreactants. The presence of IgM deposition was associated with gastrointestinal involvement ($p = 0.037$). Meanwhile, C3 deposition correlated with fever ($p = 0.027$) and deeper dermal inflammatory infiltration on histopathology ($p = 0.017$). This deeper inflammatory infiltration was also associated with renal involvement ($p = 0.032$). Additionally, epidermal necrosis correlated with arthralgia ($p = 0.001$) and renal involvement ($p = 0.019$). **Conclusion:** DIF and histopathological parameters provide complementary insights into the risk of systemic involvement in LCV. Specific findings—particularly C3 and IgM deposition, deeper dermal inflammation, and epidermal necrosis—may serve as valuable prognostic indicators to identify patients at

higher risk for systemic manifestations. Nevertheless, given the small sample size and the limited number of systemic events, the possibility of type I error from multiple comparisons cannot be excluded. Therefore, these significant associations should be interpreted as exploratory and hypothesis-generating findings. This association should be recognized and monitored in future cases.

Keywords

Leukocytoclastic Vasculitis, Direct Immunofluorescence, Histopathology, Systemic Involvement

1. Introduction

Cutaneous leukocytoclastic vasculitis (LCV) is the most common form of small-vessel vasculitis, primarily involving postcapillary venules in the dermis. LCV is histologically defined by perivascular neutrophilic infiltration, leukocytoclasia, fibrinoid necrosis and red blood cell extravasation. Clinically, it presents as palpable purpura, often on the lower extremities, but may also appear as petechiae, vesicles or ulcers [1] [2]. The pathogenesis of LCV is typically mediated by immune complex deposition in post-capillary venules. This process triggers the complement system, leading to the recruitment of neutrophils and other inflammatory cells, resulting in vascular wall destruction [3] [4].

Vasculitis can have idiopathic etiologies or be secondary to drug ingestion, infections or part of systemic diseases [1] [3]. Although most cases are self-limiting, some patients develop systemic involvement, particularly affecting the kidneys, gastrointestinal (GI) tract or joints. Early identification of systemic disease is crucial for guiding treatment and improving outcomes [5].

Direct immunofluorescence (DIF) can help diagnose specific types of vasculitis and possibly identify the underlying etiologies, systemic involvement and prognostic significance [2] [4] [6] [7]. Nevertheless, assessing systemic involvement and prognostic significance is controversial and remains unclear [2] [4] [5].

This study aimed to evaluate the correlation between DIF findings and clinical features, including systemic involvement and disease prognosis among patients with cutaneous LCV [2] [5]. The primary objective of this study was to assess the usefulness of histopathological features and DIF in diagnosing and predicting the severity of cutaneous LCV. A secondary objective was to examine the correlation of severity of histopathological features with clinical features and disease severity among patients with LCV.

2. Materials and Methods

A retrospective cohort study was conducted at the Division of Dermatology, Department of Medicine, Phramongkutklao Hospital, Bangkok, Thailand. This study was approved by the institutional review board of the Royal Thai Army Medical

Department (IRBRTA0733/2024).

From January 2013 through December 2024, all adult patients with LCV (aged 20 years or older) with histopathological confirmation and receiving DIF regarding skin lesions were included in this study.

According to Thai law, individuals who are 20 years of age or older may legally sign medical or surgical consent forms on their own. Minors under the age of 20 require a parent or a person exercising parental power to co-sign and provide consent.

Patients with ANCA-associated vasculitis and incomplete medical records, histopathological parameters and DIF results were excluded.

Comprehensive medical record reviews were completed for all participants. These included basic demographic data, clinical manifestations, possible etiologies, systemic involvement and laboratory results as shown in **Table 1**.

Skin biopsies were performed at the 2 lesion sites. The specimen was obtained using either a 4 mm punch biopsy or incision biopsy. One specimen was placed in 10% buffered formalin and another specimen was placed in Michel's transport medium and sent to the hospital laboratory unit within 24 hours for histopathologic and DIF studies, respectively (**Table 2**).

Histopathological parameters were reviewed and analyzed by a dermatopathologist as shown in **Table 3**. The dermatopathologist did not know the clinical outcome of the cases.

The histopathological grading system employed was adapted from elements described in related reports [8]-[10]. The grading system was developed for this study by adapting individual histopathological parameters described in previous reports [8]-[10]. This composite scoring system has not been formally validated.

The histopathological grading system is as follows:

1) Fibrinoid necrosis (0: absence, 1: fibrinoid necrosis involved > 0% - 50% of vessel wall (fibrin deposits around vessel wall closely located at periphery of the vessel), 2: fibrinoid necrosis involved >50% of vessel wall or large amounts of fibrin extending in a wide area around the vessels).

2) Depth of inflammatory cells infiltration (1: upper 2/3 of reticular dermis, 2: lower 1/3 of reticular dermis, 3: subcutis. The deeper infiltration is defined as the infiltration deeper than the lower 1/3 of reticular dermis (grading 2 and 3)).

3) Intensity of inflammatory cells infiltration at perivascular and interstitial areas (0: absence, 1: inflammatory cells infiltrate > 0% - 50% of areas at perivascular and interstitial areas, 2: inflammatory cells infiltrate > 50% of areas at perivascular and interstitial areas).

4) Components of cell infiltration which are classified as predominant neutrophils, mononuclear cells and eosinophils.

5) Leukocytoclastic (0: absence, 1: leukocytoclastic > 0% - 25% of inflammatory cells, 2: leukocytoclastic > 25% - 50% of inflammatory cells, 3: leukocytoclastic > 50% of inflammatory cells).

6) Size of vessel involvement, which is classified as small, medium, and large vessels.

7) Thrombi formation (0: absence, 1: involving small vessels in papillary dermis, 2: involving vessels in upper 2/3 of reticular dermis, 3: involving vessels in upper 1/3 of reticular dermis, 4: involving vessels in subcutis).

8) Presence or absence of epidermal necrosis.

Positive DIF studies were defined by the presence of IgG, IgM, IgA, or C3 fluorescence staining in the dermal perivascular areas, visualized under a fluorescence microscope.

The definition of systemic manifestations is as follows:

1) Gastrointestinal (GI) involvement defined as clinical manifestations of bowel involvement such as bowel vasculitis, ischemia, hepatitis, pancreatitis, or GI bleeding which are confirmed by laboratory tests (e.g., stool occult blood, endoscopy, imaging or histopathology). Additionally, other causes of GI involvement such as drugs were excluded.

2) Renal involvement defined as the presence of new or worsening kidney injury due to the vasculitis. At least one of the following laboratory criteria was included, which consisted of increased serum creatinine ≥1.5 times baseline within the prior 7 days or increased serum creatinine ≥0.3 mg/dl within 48 hours, along with KDIGO 2026 clinical practice guideline for acute kidney injury (AKI) and acute kidney disease (AKD), active urine sediment (>5 RBCs/hpf or RBC cast), proteinuria (>0.5 g/24hours) or histopathologic confirmation from renal biopsy.

3) Neuropathy defined as involvement of motor, sensory, or autonomic nerves by physical examination or laboratory tests (such as nerve conduction study) without other possible causes.

4) Fever defined as body temperature > 37.8˚C from mouth temperature.

The assessment of systemic manifestations was performed during the 4 weeks following confirmation of cutaneous vasculitis.

The clinical parameters, histopathological parameters, and DIF results were analyzed.

Examples of pathological gradings were shown in Figures 1-3.

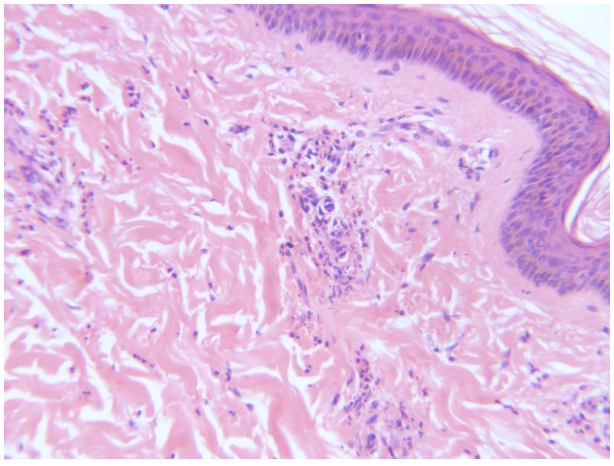

Figure 1. Histopathologic gradings of vasculitis; grade 1 of fibrinoid necrosis, grade 1 of intensity of inflammatory cells infiltration, grade 1 of leukocytoclastic and predominantly neutrophilic infiltration (H&E, x20).

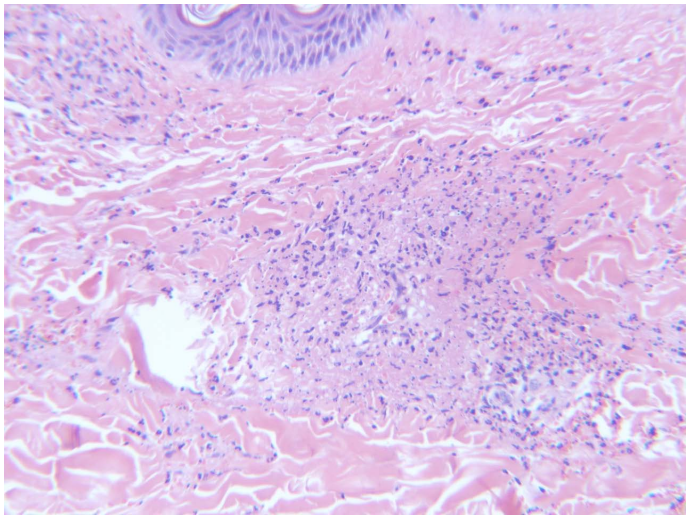

Figure 2. Histopathologic gradings of vasculitis; grade 2 of fibrinoid necrosis, grade 2 of intensity of inflammatory cells infiltration, grade 2 of leukocytoclastic and predominantly neutrophilic infiltration (H&E, x20).

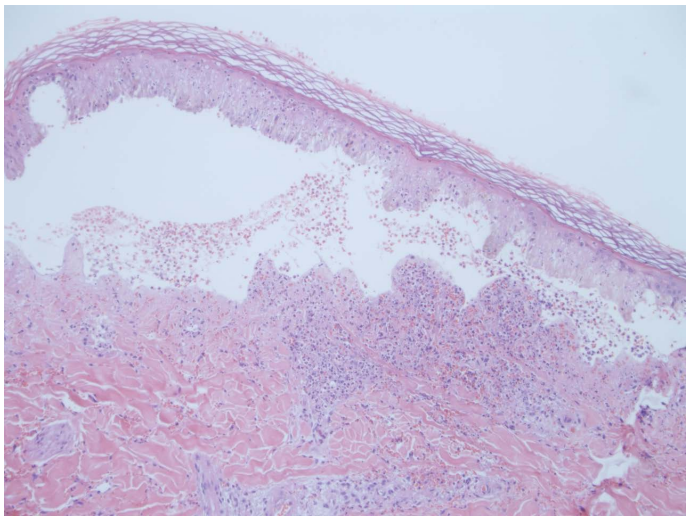

Figure 3. Histopathologic gradings of vasculitis; grade 3 of fibrinoid necrosis, grade 3 of intensity of inflammatory cells infiltration, grade 3 of leukocytoclastic and predominantly neutrophilic infiltration (H&E, x20).

3. Statistical Methods

Statistical analyses were performed using STATA/BE 17. Continuous variables were expressed as mean ± SD or median (IQR) and categorical variables as frequency (%). Group comparisons used chi-square or Fisher's exact test for categorical data and independent t-test or Mann-Whitney U test for continuous data. Associations between individual immunoreactants, histopathological parameters, and systemic involvement were assessed using univariable analyses. Multivariable logistic regression was not performed because of the limited sample size and insufficient number of events for individual systemic outcomes, with statistical significance set at $p < 0.05$.

In this study, approximately 60 total statistical comparisons were performed.

1) Comparing overall DIF-positive versus DIF-negative groups against demographic, laboratory, and histopathological data (~10 comparisons).

2) Evaluating the 4 individual immunoreactants (IgG, IgM, IgA, and C3) against specific clinical parameters and histopathological features (~40 comparisons).

3) Evaluating the direct correlation between specific histopathological features and clinical outcomes in the supplementary analysis (~10 comparisons).

4. Results

Among 57 cases of LCV, 17 did not fulfill the inclusion criteria. Finally, 40 cases were included in this study, comprising 10 male and 30 female patients (M: F ratio 1:3). The mean age of onset was 41 years (21 to 86 years). The most common cutaneous presentation was palpable purpura on the lower extremities in 39/40 (97.5%) cases. Upper extremities, trunk and face were affected in 12/40 (30%), 9/40 (22.5%) and 3/40 (7.5%) of patients, respectively. The duration from the onset of clinical symptoms to the initial clinical evaluation ranged from 1 to 365 days, with a median of 7 days. The exact duration of skin lesions prior to biopsy was not accurately documented in the medical records.

Fourteen cases (14/40, 35%) presented with extracutaneous involvement, where the musculoskeletal system was the most common finding (7/40, 17.5%), followed by renal involvement (5/40, 12.5%), fever (3/40, 7.5%), neuropathy (2/40, 5%) and gastrointestinal involvement (2/40, 5%).

Most cases did not reveal any abnormality in laboratory results. The most common abnormal laboratory finding was a positive ANA test result in 8/31 cases (25.8%), as shown in Table 1. All cases did not receive a full panel of tests, with the exception of basic lab work. This depended on the clinical manifestations of each individual.

Table 1. The demographic data, laboratory results, and histopathological parameters in negative and positive immunoreactant cases.

	DIF negative (n = 11, %)	DIF positive (n = 29, %)	p-value
Gender			0.307
Male	4 (36.4%)	6 (20.7%)	
Female	7 (63.6%)	23 (79.3%)	
Age			0.952
Mean ± sd	41.64 ± 20.43	41.17 ± 17.95	
Clinical parameters			
1. Skin involvements			
Lower extremities	11 (100%)	28 (96.6%)	0.533
Upper extremities	1 (9.1%)	11 (37.9%)	0.076

Continued

Gluteal	3 (27.3%)	4 (13.8%)	0.316
Trunk	4 (36.4%)	5 (17.2%)	0.196
Face	0 (0%)	3 (10.3%)	0.267
2. Extracutaneous involvement			
Arthralgia	3 (27.3%)	4 (13.8%)	0.316
Gastrointestinal	0 (0%)	2 (6.9%)	0.372
Neuropathy	0 (0%)	2 (6.9%)	0.372
Fever	0 (0%)	3 (10.3%)	0.267
Renal involvement	3 (27.3%)	2 (6.9%)	0.06
3. Laboratory results			
ANA (n = 31)	**DIF negative (n = 9)**	**DIF positive (n = 22)**	0.54
Negative (23/31, 74.2%)	6 (66.7%)	17 (77.3%)	
Positive (8/31, 25.8%)	3 (33.3%)	5 (22.7%)	
Low C3 and/or C4 (n = 12)	**DIF negative (n = 3)**	**DIF positive (n = 9)**	0.07
No (11/12, 91.7%)	2 (66.7%)	9 (100%)	
Yes (1/12, 8.3%)	1 (33.3%)	0 (0%)	
Cryoglobulinemia (n = 3)	**DIF negative (n = 1)**	**DIF positive (n = 2)**	N/A
No (3/3, 100%)	1 (100%)	2 (100%)	
Yes (0/3, 0%)	0 (0%)	0 (0%)	
HIV (n = 5)	**DIF negative (n = 3)**	**DIF positive (n = 2)**	
Negative (5/5, 100%)	3 (100%)	2 (100%)	N/A
Positive (0/5, 0%)	0 (0%)	0 (0%)	
HBsAg (n = 33)	**DIF negative (n = 8)**	**DIF positive (n = 25)**	0.072
Negative (30/33, 90.9%)	6 (75%)	24 (96%)	
Positive (3/33, 9.1%)	2 (25%)	1 (4%)	
Anti-HCV (n = 32)	**DIF negative (n = 8)**	**DIF positive (n = 25)**	0.32
Negative (30/32, 93.75%)	6 (85.7%)	24 (96%)	
Positive (2/32, 6.25%)	1 (14.3%)	1 (4%)	

*GI = gastrointestinal involvements (abdominal pain); *Renal involvement defined as abnormal level of serum creatinine, hematuria or proteinuria; *ANA = antinuclear antibody; **N/A due to small sample size.

Positive DIF results were found in 29/40 cases (72.5%). Among 29 cases of positive DIF, C3 was the most common positive deposition (16/29, 55.17%), followed by IgM (13/29, 44.82%), IgA (11/29, 37.93%) and IgG (3/29, 10.34%), as shown in Table 2. Regarding isolated DIF-positive results, only one immunoreactant in each case was observed in 5/29 cases (17.24%). The remaining cases were a combination of more than two positive immunoreactants, as shown in Table 2.

Table 2. Distribution of cases based on single or multiple positive immunoreactants.

Positive DIF Findings (n = 29) (%)	
Immunoreactant	Overall Positivity
IgA	11 (37.93%)
IgM	13 (44.82%)
IgG	3 (10.34%)
C3	16 (55.17%)
Immunoreactant	Isolated Positivity
IgA	4 (13.79%)
IgM	1 (3.44%)
IgG	0
C3	0
Immunoreactant	Combination of more than 2 positive immunoreactants
IgA + C3	2 (6.89%)
IgA + IgM	2 (6.89%)
IgA + IgM + C3	2 (6.89%)
IgM + C3	6 (20.68%)
IgM +IgG + C3	1 (3.44%)
IgG + C3	1 (3.44%)

Positive and negative DIF results were analyzed concerning the correlation with demographic data and laboratory results as shown in Table 1. In our retrospective cohort, female patients predominated among those with LCV; however, the difference in gender distribution between DIF-positive and DIF-negative groups did not reach statistical significance ($p = 0.307$). The mean age at onset was slightly lower in the DIF-positive group (41.17 ± 17.95 years) compared with that of the DIF-negative group (41.64 ± 20.43 years), though this difference was not statistically significant ($p = 0.952$). Extracutaneous involvements were noted in a few cases. Nevertheless, no statistical significance was observed between DIF-positive and negative groups (Table 1). Histopathological parameters also showed no significance between the two groups (Table 3).

Table 3. Histopathological parameters of cutaneous vasculitis.

Histopathological parameters			
	DIF negative N = 11 (%)	DIF positive n = 29 (%)	
Fibrinoid necrosis			0.764
Absence	1 (9.1%)	1 (3.4%)	
Involve > 0% - 50% of vessel wall	9 (81.8%)	25 (86.2%)	
>50% of vessel wall	1 (9.1%)	3 (10.3%)	

Continued

Depth of infiltrate			0.064
Upper 2/3 of reticular dermis	6 (54.5%)	17 (58.6%)	
Lower 1/3 of reticular dermis	2 (18.2%)	11 (37.9%)	
Subcutis	3 (27.3%)	1 (3.4%)	
Intensity of inflammatory cells			0.540
Absence	0 (0%)	0 (0%)	
Inflammatory cells > 0% - 50%	9 (81.8%)	21 (72.4%)	
Strong-inflammatory cells > 50%	2 (18.2%)	8 (27.6%)	
Components of cells			0.741
>75% neutrophils	0 (0%)	0 (0%)	
50% neutrophils: 50% mononuclear cells	6 (54.5%)	19 (65.5%)	
<25% neutrophils: >75% mononuclear cells	4 (36.4%)	7 (24.1%)	
Predominated eosinophils (>50%)	1 (9.1%)	3 (10.3%)	
Leukocytoclastic			0.859
Absence	0 (0%)	0 (0%)	
Leukocytoclastic > 0% - 50% of inflammatory cells	9 (81.8%)	23 (79.3%)	
Leukocytoclastic > 50% of inflammatory cells	2 (18.2%)	6 (20.7%)	
Size of vessels			0.465
Small	10 (90.9%)	28 (96.6%)	
Medium	1 (9.1%)	1 (3.4%)	
Large	0 (0%)	0 (0%)	
Thrombi			0.268
Absence	7 (63.6%)	10 (34.5%)	
Involved vessels in upper 2/3 of reticular dermis	2 (18.2%)	12 (41.4%)	
Involved vessels in lower 1/3 of reticular dermis	1 (9.1%)	6 (20.7%)	
Involved small/medium/large vessels in subcutis	1 (9.1%)	1 (3.4%)	
Epidermal necrosis			0.288
Absence	9 (81.8%)	27 (93.1%)	
Presence	2 (18.2%)	2 (6.9%)	

Although the overall distribution did not reach statistical significance, patients with positive DIF results showed a lower likelihood of renal involvement compared to the DIF-negative group ($p = 0.06$).

According to clinical parameters, the data showed that IgM-positive cases were associated with GI involvement compared with IgM-negative cases ($p = 0.037$). Additionally, C3 positive cases were significantly associated with fever compared with C3 negative cases ($p = 0.027$). No significant differences were observed regarding other clinical parameters among the remaining immunoreactants (Table 4).

Table 4. Demographic data, laboratory results and histopathological parameters according to type of positive immunoreactant.

DIF	IgG			IgM			IgA			C3		
	Negative n = 37	**Positive n = 3**	**p-value**	**Negative n = 27**	**Positive n = 13**	**p-value**	**Negative n = 28**	**Positive n = 11**	**p-value**	**Negative n = 24**	**Positive n = 16**	**p-value**
	n	**n**		**n**	**n**		**n**	**n**		**n**	**n**	
Gender			0.298			0.079			0.504			0.025*
Male	10 (27%)	0 (0%)		9 (33.3%)	1 (7.7%)		8 (28.6%)	2 (18.2%)		9 (37.5%)	1 (6.3%)	
Female	27 (73%)	3 (100%)		18 (66.7%)	12 (92.3%)		20 (71.4%)	9 (81.8%)		15 (62.5%)	15 (93.8%)	
age			0.090			0.046*			0.408			0.240
mean ± sd (years)	42.54 ± 18.58	26 ± 2.65		45.04 ± 19.15	33.54 ± 14.43		44.07 ± 18.99	36.73 ± 15.07		44.38 ± 19.96	36.69 ± 15.2	
Clinical parameters												
1. Skin involvements												
Lower extremities			0.773			0.144			0.106			0.408
No	1 (2.7%)	0 (0%)		0 (0%)	1 (7.7%)		0 (0%)	1 (9.1%)		1 (4.2%)	0 (0%)	
Yes	36 (97.3%)	3 (100%)		27 (100%)	12 (92.3%)		28 (100%)	10 (90.9%)		23 (95.8%)	16 (100%)	
Upper extremities		0.238			0.507			0.044*			0.573	
No	25 (67.6)	3 (100%)		18 (66.7%)	10 (76.9%)		22 (78.6%)	5 (45.5%)		16 (66.7%)	12 (75%)	
Yes	12 (32.4)	0 (0%)		9 (33.3%)	3 (23.1%)		6 (21.4%)	6 (54.5%)		8 (33.3%)	4 (25%)	
Gluteal			0.407			0.257			0.366			0.497
No	30 (81.1)	3 (100%)		21 (77.8%)	12 (92.3%)		22 (78.6%)	10 (90.9%)		19 (79.2%)	14 (87.5%)	
Yes	7 (18.9%)	0 (0%)		6 (22.2%)	1 (7.7%)		6 (21.4%)	1 (9.1%)		5 (20.8%)	2 (12.5%)	
Trunk			0.332			0.120			0.268			0.643
no	28 (75.5%)	3 (100%)		19 (70.4%)	12 (92.3%)		21 (75%)	10 (90.9%)		18 (75%)	13 (81.3%)	
yes	9 (24.3%)	0 (0%)		8 (29.6%)	1 (7.7%)		7 (25%)	1 (9.1%)		6 (25%)	3 (18.8%)	
Face			0.608			0.189			0.123			0.806
No	34 (91.9%)	3 (100%)		26 (96.3%)	11 (84.6%)		27 (96.4%)	9 (81.8%)		22 (91.7%)	15 (93.8%)	
Yes	3 (8.1%)	0 (0%)		1 (3.7%)	2 (15.4%)		1 (3.6%)	2 (18.2%)		2 (8.3%)	1 (6.3%)	
2. Extracutaneous involvements												
arthralgia			0.407			0.125			0.981			0.865
No	30 (81.1%)	3 (100%)		24 (88.9%)	9 (69.2%)		23 (82.1%)	9 (81.8%)		20 (83.3%)	13 (81.3%)	
Yes	7 (18.9%)	0 (0%)		3 (11.1%)	4 (30.8%)		5 (17.9%)	2 (18.2%)		4 (16.7%)	3 (18.8%)	
GI			0.679			0.037*			0.363			0.076
No	35 (94.6%)	3 (100%)		27 (100%)	11 (84.6%)		26 (92.9%)	11 (100%)		24 (100%)	14 (87.5%)	
Yes	2 (5.4%)	0 (0%)		0 (0%)	2 (15.4%)		2 (7.1%)	0 (0%)		0 (0%)	2 (12.5%)	
Neuropathy			0.679			0.588			0.363			0.767
No	35 (94.6%)	3 (100%)		26 (96.3%)	12 (92.3%)		26 (92.9%)	11 (100%)		23 (95.8%)	15 (93.8%)	
Yes	2 (5.4%)	0 (0%)		1 (3.7%)	1 (7.7%)		2 (7.1%)	0 (0%)		1 (4.2%)	1 (6.3%)	
Fever			0.608			0.189			0.258			0.027*
No	34 (91.9%)	3 (100%)		26 (96.3%)	11 (84.6%)		25 (89.3%)	11 (100%)		24 (100%)	13 (81.3%)	
Yes	3 (8.1%)	0 (0%)		1 (3.7%)	2 (15.4%)		3 (10.7%)	0 (0%)		0 (0%)	3 (18.8%)	

Continued

Renal dysfunction			0.489			0.498			0.177			0.306
Normal	31 (86.1%)	3 (100%)		22 (84.6%)	12 (92.3%)		23 (85.2%)	11 (100%)		19 (82.6%)	15 (93.8%)	
Abnormal	5 (13.9%)	0 (0%)		4 (15.4%)	1 (7.7%)		4 (14.8%)	0 (0%)		4 (17.4%)	1 (6.3%)	
3. Laboratory results	**IgG**			**IgM**			**IgA**			**C3**		
ANA (n = 31)	**Positive (n = 29)**	**Negative (n = 2)**	0.419	**Positive (n = 20)**	**Negative (n = 11)**	0.115	**Positive (n = 21)**	**Negative (n = 9)**	0.300	**Positive (n = 18)**	**Negative (n = 13)**	0.260
Negative	22 (75.9%)	1 (50%)		13 (65%)	10 (90.9%)		15 (71.4%)	8 (88.9%)		12 (66.7%)	11 (84.6%)	
Positive	7 (24.1%)	1 (50%)		7 (35%)	1 (9.1%)		6 (28.6%)	1 (11.1%)		6 (33.3%)	2 (15.4%)	
Low C3 and/orC4 (n = 12)	**Positive (n = 11)**	**Negative (n = 1)**	0.753	**Positive (n = 8)**	**Negative (n = 4)**	0.460	**Positive (n = 8)**	**Negative (n = 4)**	0.521	**Positive (n = 7)**	**Negative (n = 5)**	0.377
No	10 (90.9%)	1 (100%)		7 (87.5%)	4 (100%)		7 (87.5%)	4(100%)		6 (85.7%)	5 (100%)	
Yes	1 (9.1%)	0 (0%)		1 (12.5%)	0 (0%)		1 (12.5%)	0 (0%)		1 (14.3%)	0 (0%)	
Cryoglobulinemia (n = 3)	**Positive (n = 3)**	**Negative (n = 0)**	N/A	**Positive (n = 1)**	**Negative (n = 2)**	N/A	**Positive (n = 2)**	**Negative (n = 1)**	N/A	**Positive (n = 1)**	**Negative (n = 2)**	N/A
No	3 (100%)	0 (0%)		1 (100%)	2 (100%)		2 (100%)	1 (100%)		1 (100%)	2 (100%)	
Yes	0 (0%)	0 (0%)		0 (0%)	0 (0%)		0 (0%)	0 (0%)		0 (0%)	0 (0%)	
HIV (n = 5)	**Positive (n = 5)**	**Negative (n = 0)**	N/A	**Positive (n = 4)**	**Negative (n = 1)**	N/A	**Positive (n = 4)**	**Negative (n = 1)**	N/A	**Positive (n = 4)**	**Negative (n = 1)**	N/A
Negative	5 (100%)	0 (0%)		4 (100%)	1 (100%)		4 (100%)	1 (100%)		4 (100%)	1 (100%)	
Positive	0 (0%)	0 (0%)		0 (0%)	0 (0%)		0 (0%)	0 (0%)		0 (0%)	0 (0%)	
HBsAg (n = 33)	**Positive (n = 31)**	**Negative (n = 2)**	0.645	**Positive (n = 22)**	**Negative (n = 11)**	0.199	**Positive (n = 23)**	**Negative (n = 9)**	0.833	**Positive (n = 21)**	**Negative (n = 12)**	0.909
Negative	28 (90.3%)	2 (100%)		19 (86.4%)	11 (100%)		21 (91.3%)	8 (88.9%)		19 (90.5%)	11 (91.7%)	
Positive	3 (9.7%)	0 (0%)		3 (13.6%)	0 (0%)		2 (8.7%)	1 (11.1%)		2 (9.5%)	1 (8.3%)	
Anti-HCV (n = 32)	**Positive (n = 30)**	**Negative (n = 2)**	0.706	**Positive (n = 21)**	**Negative (n = 11)**	0.631	**Positive (n = 22)**	**Negative (n = 9)**	0.350	**Positive (n = 20)**	**Negative (n = 12)**	0.706
Negative	28 (93.3%)	2 (100%)		20 (95.2%)	10 (90.9%)		20 (90.9%)	9 (100%)		19 (95%)	11 (91.7%)	
Positive	2 (6.7%)	0 (0%)		1 (4.8%)	1 (9.1%)		2 (9.1%)	0 (0%)		1 (5%)	1 (8.3%)	
4. Histopathological parameters	**IgG**			**IgM**			**IgA**			**C3**		
	Negative n = 37	**Positive n = 3**		**Negative n = 27**	**Positive n = 13**		**Negative n = 28**	**Positive n = 11**		**Negative n = 24**	**Positive n = 16**	
Fibrinoid necrosis			0.751			0.467			0.645			0.863
Absence	2 (5.4%)	0 (0%)		2 (7.4%)	0 (0%)		2 (7.1%)	0 (0%)		1 (4.2%)	1 (6.3%)	
Involve > 0% - 50% of vessel wall	31 (83.8%)	3 (100%)		23 (85.2%)	11 (84.6%)		23 (82.1%)	10 (90.9%)		21 (87.5%)	13 (81.3%)	
>50% of vessel wall	4 (10.8%)	0 (0%)		2 (7.4%)	2 (15.4%)		3 (10.7%)	1 (9.1%)		2 (8.3%)	2 (12.5%)	
Depth of infiltrate			0.403			0.441			0.166			0.017*
Upper 2/3 of reticular dermis	22 (59.5%)	1 (33.3%)		17 (63%)	6 (46.2%)		14 (50%)	9 (81.8%)		16 (66.7%)	7 (43.8%)	
Lower 1/3 of reticular dermis	11 (29.7%)	2 (66.7%)		7 (25.9%)	6 (46.2%)		11 (39.3%)	2 (18.2%)		4 (16.7%)	9 (56.3%)	
Subcutis	4 (10.8%)	0 (0%)		3 (11.1%)	1 (7.7%)		3 (10.7%)	0 (0%)		4 (16.7%)	0 (0%)	
Intensity of inflammatory cells		0.298				0.172			0.697			1.000
Absence	0 (0%)	0 (0%)		0 (0%)	0 (0%)		0 (0%)	0 (0%)		0 (0%)	0 (0%)	

Continued

Inflammatory cells > 0% - 50%	27 (73%)	3 (100%)		22 (81.5%)	8 (61.5%)		22 (78.6%)	8 (72.7%)		18 (75%)	12 (75%)	
Strong - inflammatory cells > 50%	10 (27%)	0 (0%)		5 (18.5%)	5 (38.5%)		6 (21.4%)	3 (27.3%)		6 (25%)	4 (25%)	
Components of cells			0.830			0.343			0.982			0.162
>75% neutrophils	0 (0%)	0 (0%)		0 (0%)	0 (0%)		0 (0%)	0 (0%)		0 (0%)	0 (0%)	
50% neutrophils: 50% mononuclear cells	23 (62.2%)	2 (66.7%)		16 (59.3%)	9 (69.2%)		18 (64.3%)	7 (63.6%)		15 (62.5%)	10 (62.5%)	
<25% neutrophils: >75% mononuclear cells	10 (27%)	1 (33.3%)		7 (25.9%)	4 (30.8%)		7 (25%)	3 (27.3%)		5 (20.8%)	6 (37.5%)	
Predominated eosinophils (>50%)	4 (10.8%)	0 (0%)		4 (14.8%)	0 (0%)		3 (10.7%)	1 (9.1%)		4 (16.7%)	0 (0%)	
Leukocytoclastic			0.368			0.736			0.821			0.333
Absence	0 (0%)	0 (0%)		0 (0%)	0 (0%)		0 (0%)	0 (0%)		0 (0%)	0 (0%)	
Leukocytoclastic > 0% - 50% of inflammatory cells	29 (78.4%)	3 (100%)		22 (81.5%)	10 (76.9%)		22 (78.6%)	9 (81.8%)		18 (75%)	14 (87.5%)	
Leukocytoclastic > 50% of inflammatory cells	8 (21.6%)	0 (0%)		5 (18.5%)	3 (23.1%)		6 (21.4%)	2 (18.2%)		6 (25%)	2 (12.5%)	
Size of vessels			0.679			0.314			0.363			0.236
Small	35 (94.6%)	3 (100%)		25 (92.6%)	13 (100%)		26 (92.9%)	11 (100%)		22 (91.7%)	16 (100%)	
Medium	2 (5.4%)	0 (0%)		2 (7.4%)	0 (0%)		2 (7.1%)	0 (0%)		2 (8.3%)	0 (0%)	
Large	0 (0%)	0 (0%)		0 (0%)	0 (0%)		0 (0%)	0 (0%)		0 (0%)	0 (0%)	
Thrombi			0.875			0.389			0.395			0.312
Absence	16 (43.2%)	1 (33.3%)		14 (51.9%)	3 (23.1%)		13 (46.4%)	3 (27.3%)		12 (50%)	5 (31.3%)	
Involved vessels in upper 2/3 of reticular dermis	13 (35.1%)	1 (33.3%)		8 (29.6%)	6 (46.2%)		8 (28.6%)	6 (54.5%)		7 (29.2%)	7 (43.8%)	
Involved vessels in lower 1/3 of reticular dermis	6 (16.2%)	1 (33.3%)		4 (14.8%)	3 (23.1%)		5 (17.9%)	2 (18.2%)		3 (12.5%)	4 (25%)	
Involved small/ medium/large vessels in subcutis	2 (5.4%)	0 (0%)		1 (3.7%)	1 (7.7%)		2 (7.1%)	0 (0%)		2 (8.3%)	0 (0%)	
Epidermal necrosis			0.548			0.431			0.186			0.667
Absence	33 (89.2%)	3 (100%)		25 (92.6%)	11 (84.6%)		24 (85.7%)	11 (100%)		22 (91.7%)	14 (87.5%)	
Presence	4 (10.8%)	0 (0%)		2 (7.4%)	2 (15.4%)		4 (14.3%)	0 (0%)		2 (8.3%)	2 (12.5%)	

C3 positive cases were also significantly associated with deeper inflammatory cell infiltration compared with C3-negative cases ($p = 0.017$). The remaining immunoreactants did not show significant changes in other histopathological parameters (Table 4).

Regarding histopathological features, deeper dermal infiltrates were significantly correlated with renal involvement ($p = 0.032$). Additionally, the presence of epidermal necrosis was significantly associated with arthralgia ($p = 0.001$) and renal involvement ($p = 0.019$) (see Supplement).

5. Discussion

Cutaneous leukocytoclastic vasculitis (LCV) is a form of small-vessel vasculitis characterized by immune complex deposition in postcapillary venules. Although typically self-limited, LCV may be associated with systemic involvement, particularly affecting the renal, GI and musculoskeletal systems. While DIF is widely used for diagnostic confirmation, its usefulness in diagnosing and predicting the severity of cutaneous LCV remains poorly defined.

In this study, positive DIF was observed in 72.5% of the cases. The rate is consistent with related reports ranging from 50% to 80% in biopsy-confirmed cases [11]-[13].

Although DIF negativity may suggest ANCA-associated vasculitis, it remains inconclusive. One major limitation is that DIF positivity depends on the age of the cutaneous lesion.

The ideal timing for DIF biopsy is within 8 to 24 hours of lesion onset [4] [14]. DIF positive rates were reported in 85% of cases when biopsied within seven days, compared to only 14% after one week [14].

The duration from the onset of clinical symptoms to the initial clinical evaluation ranged from 1 to 365 days, with a median of 7 days. However, the specific time elapsed between the appearance of cutaneous lesions and the biopsy was not recorded. For this reason, a negative DIF result may be a consequence of biopsy timing, rather than a true absence of immune complex deposition.

When comparing baseline characteristics between DIF-positive and DIF-negative groups, no significant differences were observed concerning demographic data, clinical manifestations, laboratory results and histopathological parameters.

In the DIF-positive group, C3 was the most frequently detected immune reactant regarding DIF, similar to related reports [4] [11] [12] [15] [16]. Each immunoreactant was analyzed. We found C3-positive cases were associated with fever and deeper inflammatory cells infiltration in histopathology features and IgM-positive cases were associated with GI involvement (abdominal pain and abnormal liver function tests).

This can be explained by activation of the complement pathway leading to production of anaphylatoxin, activation of various inflammatory cells to produce various cytokines altering the hypothalamus set point and producing fever and causing inflammation in many tissues [17] [18].

The association of IgM positivity in GI involvement has not been reported in LCV. The role of IgM involvement has been reported in a group of IgA vasculitis or Henoch-Schonlein purpura (HSP). The association in the presentation of IgM along with IgA deposition in cutaneous lesions was observed with renal involvement [6] [7].

In cutaneous LCV, there was reported of the absence of IgM deposition was reported to be significantly associated with renal involvement [4].

Two of the IgA-positive DIF cases, either isolated or combined positive (2/29, 6.89%) were diagnosed with IgA vasculitis according to the EULAR classification

criteria for HSP [19].

In contrast to related reports, a stronger correlation between IgA deposition and systemic symptoms was found, particularly renal and GI involvement [13] [16]. Our cases did not demonstrate an association regarding IgA positivity in systemic involvement, including renal, GI or abnormal laboratory results. Although systemic involvement was frequently noted in IgA vasculitis, the absence of systemic involvement was observed. Arthralgia, GI and renal involvement presented in only 30% to 50% of the reported IgA-positive cases [20] [21]. The absence of systemic involvement in our cases may have stemmed from the very small number of cases, less severe clinical presentations or only skin-limited IgA vasculitis [22]. Moreover, this finding is consistent with related reports in which IgA-positive cases did not always correspond to clinically significant extracutaneous disease [2] [11] [12] [15].

Based on histopathological features, we demonstrated an association of deeper dermal infiltration with renal involvement ($p = 0.032$). Additionally, the presence of epidermal necrosis was associated with arthralgia ($p = 0.001$) and renal involvement ($p = 0.019$).

The severity of histopathological parameters and the association of systemic involvement were noted in variable results. One study did not demonstrate any correlation of severity of histopathological parameters and systemic involvement [8]. The association of deeper infiltration, pulmonary involvement and cutaneous ulceration has been reported [10]. The report regarding deeper inflammatory infiltrates was linked to more extensive systemic disease including malignancy and connective tissue disorders [23]. Additionally, the association with severity of vessel wall changes, the amount of exocytosis, the amount of leukocytoclasis, the severity of fibrinoid necrosis and clinical severity was reported [10]. The presence of epidermal necrosis was also reported associated with nephritis among patients with IgA vasculitis [24].

However, histopathological change in LCV depends on clinical presentations and time of biopsy [1]. The time to biopsy LCV lesions is important. When lesions are older than 48 hours, the neutrophils begin to be replaced by lymphocyte-rich infiltration [1].

The variables in histopathological parameters and positive DIF mainly depend on the interval between time to biopsy and cutaneous lesion onset. A late biopsy (more than 48 hours) can result in less severe histopathological parameters and negative DIF [25] [26]. The exact duration of skin lesions prior to biopsy was not accurately documented in the medical records. However, we analyzed data from the onset of clinical symptoms to the initial clinical evaluation, which demonstrated the full spectrum of histopathological features of vasculitis when the symptom- onset-to-initial-evaluation interval was within 7 days (see Supplement).

Due to immunoreaction clearance in late-phase lesions, this temporal variation may partly explain why patients with systemic involvement present negative DIF findings.

The strength of this study lies in its integrated clinicopathologic design, encompassing clinical features, detailed histopathological grading and DIF findings across a 12-year retrospective cohort.

All skin biopsies were evaluated by a dermatopathologist using a histologic severity scoring system, improving internal consistency and allowing correlation with systemic features.

However, several limitations were identified. First, this constituted a retrospective cohort study, which may introduce incomplete data and information bias, particularly related to documentation quality and timing of evaluations. Second, the sample size, particularly within subgroups, was limited, thereby reducing the statistical power to detect weaker associations. Consequently, some subgroup analyses involved sample sizes too small to guarantee that the observed relationships reflect true associations.

Given the small sample size and the limited number of systemic events, particularly for gastrointestinal involvement and fever, the possibility of type I error from multiple comparisons cannot be excluded. Therefore, these significant associations should be interpreted as exploratory and hypothesis-generating findings. This association should be recognized and monitored in future cases.

Larger sample sizes will be required to definitively identify and confirm these relationships.

Thirdly, although our DIF assessments were semi-quantitative and performed by an experienced dermatopathologist, interobserver variability in DIF interpretation remains a potential confounder in multicenter replication settings.

Additionally, all biopsy specimens were evaluated by a single, experienced dermatopathologist using a specific histopathological grading system. A single observer was intentionally utilized to ensure interpretive consistency and minimize interobserver variability across all cases. However, it should be noted that the histopathological grading system employed in this study has not been formally validated, and interobserver agreement was not assessed; instead, our evaluations were conducted in alignment with parameters established in previous literature.

Finally, the exact duration of skin lesions prior to biopsy was not accurately documented in the medical records. There may be limited interpretation of DIF-negative findings and histopathological severity.

Future studies concerning LCV should focus on prospective, multicenter designs to validate the prognostic significance of DIF in predicting systemic involvement. Standardizing the timing of biopsies relative to lesion onset would clarify the temporal dynamics of immune complex deposition and improve DIF interpretability. Integration of serologic biomarkers such as complement levels, cytokine profiles or ANCA subtypes, alongside histopathological grading, may enhance risk stratification. Developing a composite clinicopathologic severity index could support personalized prognostic assessment and therapeutic decision-making.

Broader inclusion of pediatric, elderly and immunocompromised populations

will further enrich understanding of disease variability across demographic and immunologic contexts.

6. Conclusion

In conclusion, our findings suggest that while direct immunofluorescence (DIF) plays a limited role in definitively establishing the diagnosis of cutaneous leukocytoclastic vasculitis (LCV), combining DIF findings with selected histopathological parameters can enhance the early stratification of disease severity and systemic risk. Consequently, careful clinical workup and rigorous follow-up are warranted for this patient subgroup. While these insights may help clinicians identify patients who require closer systemic evaluation, they should be considered exploratory and require validation in larger, prospective cohorts.

Author Contributions

Chutika Srisuttiyakorn

- Conceptualized the study;
- Conducted the investigations;
- Wrote the original draft and wrote all the review and editing manuscript;
- Supervision.

Sirada Srithanetsakul

- Performed the methodology and data analysis;
- Conducted the investigations;
- Wrote the original draft.

All authors reviewed, edited, and approved the final manuscript.

Conflicts of Interest

The authors declare no conflicts of interest regarding the publication of this paper.

References

[1] Carlson, J.A., Ng, B.T. and Chen, K. (2005) Cutaneous Vasculitis Update: Diagnostic Criteria, Classification, Epidemiology, Etiology, Pathogenesis, Evaluation and Prognosis. *The American Journal of Dermatopathology*, **27**, 504-528. https://doi.org/10.1097/01.dad.0000181109.54532.c5

[2] Lath, K., Chatterjee, D., Saikia, U.N., Saikia, B., Minz, R., De, D., *et al.* (2018) Role of Direct Immunofluorescence in Cutaneous Small-Vessel Vasculitis: Experience from a Tertiary Center. *The American Journal of Dermatopathology*, **40**, 661-666. https://doi.org/10.1097/dad.0000000000001170

[3] Micheletti, R.G. (2021) Cutaneous Vasculitis. In: Bolognia, J.L., Schaffer, J.V. and Cerroni, L., Eds., *Dermatology*, 5th Edition, Elsevier, 418-449.

[4] Ertekin, S.S., Koku Aksu, A.E., Leblebici, C., Erdemir, V.A., Erdem, O., Bal Avcı, E., *et al.* (2023) Systemic Disease in Leukocytoclastic Vasculitis: A Focus on Direct Immunofluorescence Findings. *Anais Brasileiros de Dermatologia*, **98**, 59-67. https://doi.org/10.1016/j.abd.2021.11.009

[5] Micheletti, R.G. (2023) Cutaneous Small Vessel Vasculitis: A Practical Guide to Di-

agnosis and Management. *American Journal of Clinical Dermatology*, **24**, 89-95. https://doi.org/10.1007/s40257-022-00736-6

[6] Belli, A.A. and Dervis, E. (2014) The Correlation between Cutaneous IgM Deposition and Renal Involvement in Adult Patients with Henoch-Schönlein Purpura. *European Journal of Dermatology*, **24**, 81-84. https://doi.org/10.1684/ejd.2013.2243

[7] Takeuchi, S., Soma, Y. and Kawakami, T. (2010) IgM in Lesional Skin of Adults with Henoch-Schönlein Purpura Is an Indication of Renal Involvement. *Journal of the American Academy of Dermatology*, **63**, 1026-1029. https://doi.org/10.1016/j.jaad.2009.11.690

[8] Cribier, B., Couilliet, D., Meyer, P. and Grosshans, E. (1999) The Severity of Histopathological Changes of Leukocytoclastic Vasculitis Is Not Predictive of Extracutaneous Involvement. *The American Journal of Dermatopathology*, **21**, 532-536. https://doi.org/10.1097/00000372-199912000-00005

[9] Zax, R.H., Hodge, S.J. and Callen, J.P. (1990) Cutaneous Leukocytoclastic Vasculitis. Serial Histopathologic Evaluation Demonstrates the Dynamic Nature of the Infiltrate. *Archives of Dermatology*, **126**, 69-72. https://doi.org/10.1001/archderm.1990.01670250075012

[10] Hodge, S.J., Callen, J.P. and Ekenstam, E. (1987) Cutaneous Leukocytoclastic Vasculitis: Correlation of Histopathological Changes with Clinical Severity and Course. *Journal of Cutaneous Pathology*, **14**, 279-284. https://doi.org/10.1111/j.1600-0560.1987.tb00500.x

[11] Takatu, C.M., Heringer, A.P.R., Aoki, V., Valente, N.Y.S., de Faria Sanchez, P.C., de Carvalho, J.F., *et al.* (2017) Clinicopathologic Correlation of 282 Leukocytoclastic Vasculitis Cases in a Tertiary Hospital: A Focus on Direct Immunofluorescence Findings at the Blood Vessel Wall. *Immunologic Research*, **65**, 395-401. https://doi.org/10.1007/s12026-016-8850-6

[12] Gulseren, D., Erbağcı, E., Gököz, Ö. and Atakan, N. (2020) The Relationship between Direct Immunofluorescence Findings and Clinical and Laboratory Parameters in Patients with Cutaneous Small Vessel Vasculitis. *Turkish Journal of Dermatology*, **14**, 42-47. https://doi.org/10.4103/tjd.tjd_13_20

[13] Alalwani, M., Billings, S.D. and Gota, C.E. (2014) Clinical Significance of Immunoglobulin Deposition in Leukocytoclastic Vasculitis: A 5-Year Retrospective Study of 88 Patients at Cleveland Clinic. *The American Journal of Dermatopathology*, **36**, 723-729. https://doi.org/10.1097/dad.0000000000000122

[14] Nandeesh, B. and Tirumalae, R. (2013) Direct Immunofluorescence in Cutaneous Vasculitis: Experience from a Referral Hospital in India. *Indian Journal of Dermatology*, **58**, 22-25. https://doi.org/10.4103/0019-5154.105280

[15] Sais, G., Vidaller, A., Jucglà, A., Servitje, O., Condom, E. and Peyrí, J. (1998) Prognostic Factors in Leukocytoclastic Vasculitis: A Clinicopathologic Study of 160 Patients. *Archives of Dermatology*, **134**, 309-315. https://doi.org/10.1001/archderm.134.3.309

[16] Barnadas, M.A., Pérez, E., Gich, I., Llobet, J.M., Ballarín, J., Calero, F., *et al.* (2003) Diagnostic, Prognostic and Pathogenic Value of the Direct Immunofluorescence Test in Cutaneous Leukocytoclastic Vasculitis. *International Journal of Dermatology*, **43**, 19-26. https://doi.org/10.1111/j.1365-4632.2004.01714.x

[17] Ostrycharz, E. and Hukowska-Szematowicz, B. (2022) New Insights into the Role of the Complement System in Human Viral Diseases. *Biomolecules*, **12**, Article No. 226. https://doi.org/10.3390/biom12020226

[18] El-Radhi, A.S. (2018) Pathogenesis of Fever. In: Sahib El-Radhi, A., Ed., *Clinical Man-*

ual of Fever in Children, 2nd Edition, Springer International Publishing, 53-68. https://doi.org/10.1007/978-3-319-92336-9_3

[19] Ozen, S., Pistorio, A., Iusan, S.M., Bakkaloglu, A., Herlin, T., Brik, R., *et al.* (2010) EULAR/PRINTO/PRES Criteria for Henoch-Schönlein Purpura, Childhood Polyarteritis Nodosa, Childhood Wegener Granulomatosis and Childhood Takayasu Arteritis: Ankara 2008. Part II: Final Classification Criteria. *Annals of the Rheumatic Diseases*, **69**, 798-806. https://doi.org/10.1136/ard.2009.116657

[20] Hočevar, A., Rotar, Z., Jurčić, V., Pižem, J., Čučnik, S., Vizjak, A., *et al.* (2016) IgA Vasculitis in Adults: The Performance of the EULAR/PRINTO/PRES Classification Criteria in Adults. *Arthritis Research & Therapy*, **18**, Article No. 58. https://doi.org/10.1186/s13075-016-0959-4

[21] Yong, A.M., Lee, S.X. and Tay, Y. (2015) The Profile of Adult Onset Henoch-Schönlein Purpura in an Asian Population. *International Journal of Dermatology*, **54**, 1236-1241. https://doi.org/10.1111/ijd.12732

[22] Kawamura, M., Mizutani, Y., Mizutani, Y., Matsuyama, K., Shu, E., Miyazaki, T., *et al.* (2021) Clinical and Pathological Differences between Skin-Limited IgM/IgG Vasculitis and Skin-Limited IgA Vasculitis. *Journal of Cutaneous Immunology and Allergy*, **4**, 28-33. https://doi.org/10.1002/cia2.12156

[23] Sanchez, N.P., Van Hale, H.M. and Su, W.P. (1985) Clinical and Histopathologic Spectrum of Necrotizing Vasculitis. Report of Findings in 101 Cases. *Archives of Dermatology*, **121**, 220-224. https://doi.org/10.1001/archderm.1985.01660020078022

[24] Srivastava, A., Choudhary, S., Chellappan, A. and Choudhary, R. (2023) Necrotic Skin Lesion as the First Manifestation of IgA Vasculitis with Nephritis. *BMJ Case Reports*, **16**, e255823. https://doi.org/10.1136/bcr-2023-255823

[25] Inamadar, A.C. and Palit, A. (2009) Childhood Cutaneous Vasculitis: A Comprehensive Appraisal. *Indian Journal of Dermatology*, **54**, 110-117. https://doi.org/10.4103/0019-5154.53179

[26] Braverman, I.M. and Yen, A. (1975) Demonstration of Immune Complexes in Spontaneous and Histamine-Induced Lesions and in Normal Skin of Patients with Leukocytoclastic Angiitis. *Journal of Investigative Dermatology*, **64**, 105-112. https://doi.org/10.1111/1523-1747.ep12510321

Supplement

https://docs.google.com/spreadsheets/d/1nkWaYjAgdc_269u_tzGnv3G5gopKoAAv/edit?usp=drive_link&ouid=100456467508458179715&rtpof=true&sd=true