Scientific Research Publishing

Open Journal of Obstetrics and Gynecology, 2026, 16(11), 1657-1665
https://www.scirp.org/journal/ojog
ISSN Online: 2160-8806
ISSN Print: 2160-8792

Giant Mature Ovarian Teratoma Weighing 8.5 kg Managed by Laparotomy in a Young Nulligravid Woman: A Case Report from a Resource-Limited Setting in Burkina Faso

Moussa Sanogo[1*], Jean de Dieu Sanou[2], Nebon Delphine Bado[3], Sansan Rodrigue Sib[1], Ibrahim Savadogo[3], P. Rachida M. J. Drabo-Ouédraogo[1], Wendwoumyan Judicaël Congo[4], Azize Tiendrebeogo[5], Salam Ouédraogo[6], Issa Ouédraogo[1]

[1]Department of Obstetrics and Gynecology, Ouahigouya Regional University Hospital Center, Léda Bernard Ouédraogo University, Ouahigouya, Burkina Faso
[2]Department of Obstetrics and Gynecology, Sourô Sanou University Hospital Center, Nazi Boni University, Bobo-Dioulasso, Burkina Faso
[3]Department of Pathology, Ouahigouya Regional University Hospital Center, Léda Bernard Ouédraogo University, Ouahigouya, Burkina Faso
[4]Department of Radiology, Ouahigouya Regional University Hospital Center, Ouahigouya, Burkina Faso
[5]Department of Obstetrics and Gynecology, Yembila Abdoulaye Toguyeni University, Fada N'Gourma, Burkina Faso
[6]Department of General and Digestive Surgery, Ouahigouya Regional University Hospital Center, Léda Bernard Ouédraogo University, Ouahigouya, Burkina Faso
Email: *docsanogo@yahoo.fr

How to cite this paper: Sanogo, M., Sanou, J.D., Bado, N.D., Sib, S.R., Savadogo, I., Drabo-Ouédraogo, P.R.M.J., Congo, W.J., Tiendrebeogo, A., Ouédraogo, S. and Ouédraogo, I. (2026) Giant Mature Ovarian Teratoma Weighing 8.5 kg Managed by Laparotomy in a Young Nulligravid Woman: A Case Report from a Resource-Limited Setting in Burkina Faso. *Open Journal of Obstetrics and Gynecology*, **16**, 1657-1665.
https://doi.org/10.4236/ojog.2026.1611147

Received: October 23, 2026
Accepted: November 17, 2026
Published: November 20, 2026

Abstract

Mature cystic teratoma (dermoid cyst) is the most common ovarian germ cell tumor. It is usually small, and giant forms (≥15 cm) are rare. We report this case to describe the presentation and management of an exceptionally large mature teratoma in a young nulligravid woman, and to discuss the choice of surgical approach when tumor markers and laparoscopy are unavailable. A 25-year-old nulligravid woman presented with a two-year history of progressive abdominal distension, abdominopelvic pain and irregular menses. Examination revealed a firm abdominopelvic mass reaching the xiphoid process, with an abdominal girth of 105 cm. Ultrasound and computed tomography showed a well-circumscribed, mixed cystic and solid left adnexal mass measuring 31 cm, without invasion of adjacent organs; CT showed a fat-fluid level and a calcified mural nodule suggestive of mature teratoma. Tumor markers could not be measured locally. A midline laparotomy was performed, and adhesions to the ipsilateral tube led to a left salpingo-oophorectomy; the contralateral ovary appeared normal. The specimen weighed 8535 g and measured

Copyright © 2026 by author(s) and Scientific Research Publishing Inc.
This work is licensed under the Creative Commons Attribution International License (CC BY 4.0).
http://creativecommons.org/licenses/by/4.0/
Open Access

30 × 28 × 22 cm. Histology showed a mature teratoma containing skin, mature cartilage and secretory glands, with no immature component and no malignancy. Recovery was uneventful, and follow-up at six months was unremarkable. Giant mature ovarian teratomas mainly reflect delayed presentation. Where laparoscopy is not available, midline laparotomy allows safe en bloc removal; healthy ovarian tissue should be preserved whenever feasible in young women, and thorough histological sampling is required to exclude malignant transformation.

Keywords

Mature Cystic Teratoma, Dermoid Cyst, Giant Ovarian Tumor, Laparotomy, Salpingo-Oophorectomy, Burkina Faso

1. Introduction

Teratoma is the most common germ cell tumor of the ovary [1] [2]. Ovarian teratomas are classified as mature, immature or monodermal. Mature cystic teratoma, or dermoid cyst, is a benign tumor composed of well-differentiated derivatives of one or more germ layers. It can occur at any age but peaks between 20 and 40 years [2]. It accounts for 10% - 20% of all ovarian neoplasms in adults, which makes it the most frequent benign ovarian tumor in this age group, with an estimated annual incidence of 1.2 to 14.2 cases per 100,000 women [2].

Dermoid cysts are usually small, with a mean diameter of 6 to 7 cm, and they grow slowly, at about 1.8 mm per year [3]. Giant forms, defined by a maximum diameter of 15 cm or more, are uncommon. A recent review of the English- and Spanish-language literature found only 16 published cases of giant ovarian teratoma between 2003 and 2023 [3]. Such tumors are a diagnostic and surgical challenge, especially where access to imaging, tumor markers and minimally invasive surgery is limited.

We report a mature ovarian teratoma weighing 8535 g in a 25-year-old nulligravid woman, managed by laparotomy at the Ouahigouya Regional University Hospital Center, Burkina Faso. This case is reported for three reasons. First, the tumor was exceptionally large, weighing 8535 g and measuring 30 × 28 × 22 cm. Second, it was managed in a regional hospital where tumor markers and laparoscopy were not available, which shaped both diagnosis and surgery. Third, it illustrates the difficult balance between fertility preservation and safe excision in a young woman who has never been pregnant.

2. Case Presentation

2.1. History and Clinical Examination

A 25-year-old nulligravid woman presented with abdominopelvic pain and a marked, progressive increase in abdominal size over two years, associated with menstrual irregularity. Menarche had occurred at 14 years of age, and her cycles

were irregular. She was not using any contraception and had no relevant medical or surgical history.

On admission, she weighed 72 kg, was hemodynamically stable and in good general condition, with mildly pale conjunctivae. The hemoglobin level was 10 g/dL. The abdomen was considerably distended, with an abdominal girth of 105 cm and an everted umbilicus (Figure 1 and Figure 2). Palpation revealed a rounded abdominopelvic mass, firm in places, slightly fixed at the umbilicus and extending up to the xiphoid process. On speculum examination, the cervix and vaginal walls appeared normal; the vaginal fornices were filled but not tender.

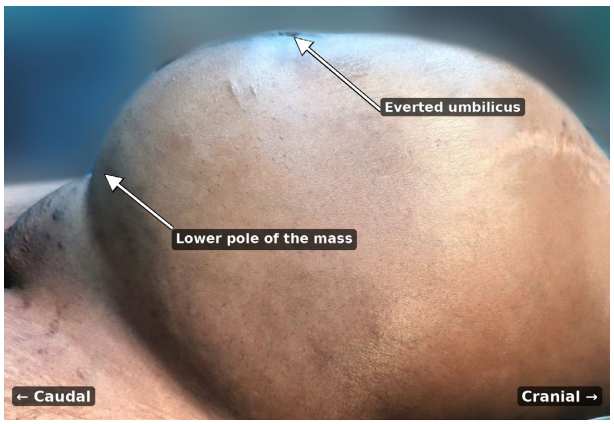

Figure 1. Preoperative lateral view of the patient lying supine (caudal end on the left, cranial end on the right). Major abdominal distension occupies almost the entire abdominal cavity, with the everted umbilicus at the top of the bulge. The background has been blurred to protect the identity of people in the room.

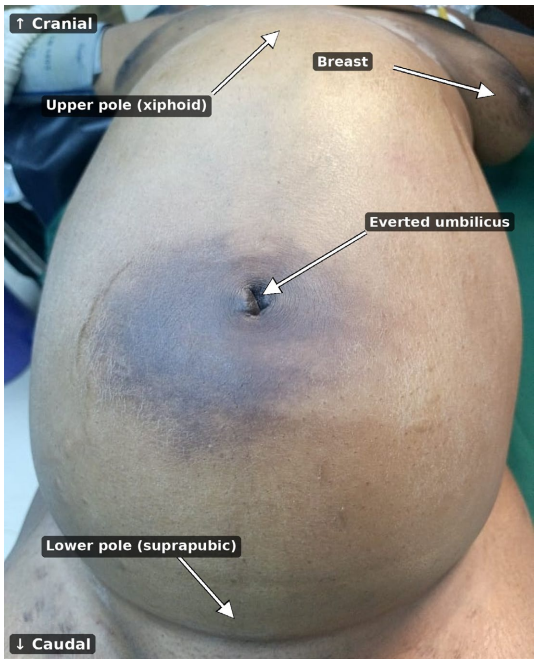

Figure 2. Preoperative frontal view (cranial end at the top). The mass extends from the suprapubic region to the xiphoid process, with an everted umbilicus.

2.2. Imaging and Laboratory Work-Up

Pelvic ultrasound showed a normal-sized uterus with a thin endometrium; the right ovary was not visualized. There was a large, well-circumscribed mass, most likely arising from the left ovary, measuring 31 cm in its greatest dimension. It contained both cystic and solid components. Color Doppler showed peripheral flow without disorganized central vascularity. Abdominopelvic computed tomography (CT) confirmed a large heterogeneous mass that displaced adjacent organs without clear invasion of neighboring structures. On contrast-enhanced CT, the lesion was a heterogeneous, predominantly cystic ovarian mass with well-defined, sharp margins, no infiltration of surrounding tissues, and moderate heterogeneous enhancement. The cystic component had mixed attenuation (−78 to 8 HU) and contained a fat-fluid level. The solid component was a nodular mural structure containing fine calcifications, consistent with a Rokitansky nodule. The preoperative diagnosis was therefore a probable mature cystic teratoma. Serum tumor markers (CA-125 and CA 19-9) could not be measured because these tests were not available locally.

2.3. Surgical Management

After a complete preoperative work-up and anesthetic assessment, a midline supra- and infra-umbilical laparotomy was performed. Exploration confirmed that the mass arose from the left ovary. Because of the size of the tumor and its adhesions to the ipsilateral fallopian tube, a left salpingo-oophorectomy was performed and the mass was removed en bloc. The contralateral ovary was of normal size and macroscopically healthy, and no peritoneal implants were found. Estimated blood loss was 100 mL, and no transfusion was required. The operative report did not document whether residual healthy ovarian tissue was present on the left side. Given the size of the tumor and its adhesions to the tube, an attempted cystectomy was judged to carry a high risk of rupture and spillage, and salpingo-oophorectomy was therefore preferred.

The postoperative course was uneventful. The patient was discharged on postoperative day 5, and follow-up to six months showed no abnormality.

2.4. Pathological Findings

On gross examination, the specimen was an ovarian cystic mass weighing 8535 g and measuring 30 × 28 × 22 cm (**Figure 3**). Its external surface was multinodular and whitish to blackish, and its consistency was soft in some areas and fluid in others. The cut surface was heterogeneous, both solid and cystic, with foci of hemorrhage. The protuberance (Rokitansky nodule) was whitish and semi-firm, and the cystic component contained greenish, gelatinous material.

Microscopically, the cyst wall was lined by skin-type epithelium, thinned in places, and the lumen was filled with keratin lamellae. The protuberance contained several tissue types: skin, mature cartilage and secretory glands without atypia (**Figure 4**). No immature or malignant component was found in the sam-

pled sections. A total of 37 tissue blocks were examined, including 5 from the Rokitansky nodule, together with samples from the solid areas, the hemorrhagic areas and the cyst wall. The diagnosis of mature ovarian teratoma was made.

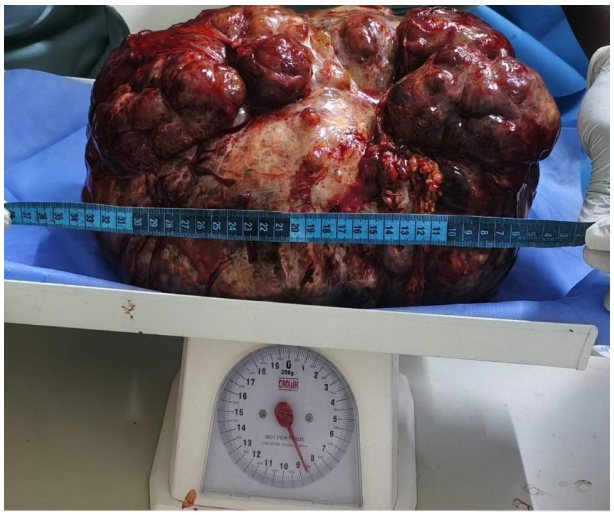

Figure 3. Gross specimen: multilobulated left ovarian mass measuring 30 × 28 × 22 cm and weighing 8535 g, shown on the scale with a measuring tape.

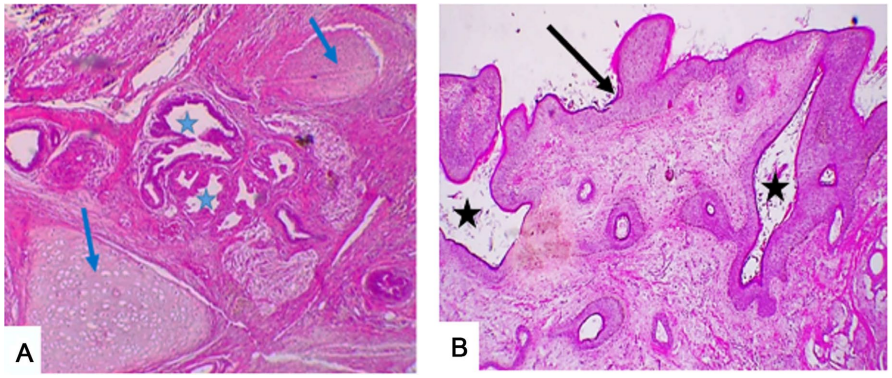

Figure 4. Microscopic appearance of the mature ovarian teratoma (hematoxylin and eosin, low magnification). (A) Multiple tissue types, with mature cartilage (blue arrows) and secretory glands without atypia (blue stars). (B) Skin-type epithelium (black arrow) lining cystic cavities that contain keratin lamellae (black stars).

3. Discussion

3.1. Epidemiology and Tumor Size

Mature cystic teratoma is the most common ovarian germ cell tumor and accounts for 10% - 20% of ovarian neoplasms in adults [2]. A similar proportion was already reported in one of the first large retrospective series on this tumor [4]. Giant forms have also been reported in sub-Saharan Africa, notably in Cotonou, Benin [5] and in Lubumbashi, Democratic Republic of the Congo [6]. In these reports, as in ours, the large size of the tumor was linked to late presentation. Such delays may result from socio-economic and cultural barriers and from the limited

availability of health services.

Giant ovarian tumors, defined by a diameter of 15 cm or more, remain rare. The review by Barragán-Curiel *et al.*, limited to English- and Spanish-language reports, identified only 16 cases of giant ovarian teratoma published between 2003 and 2023 [3]. Even larger cases have been described, such as that of a patient who had ignored her symptoms for four years [7], which shows how diagnostic delay contributes to these giant forms. With a weight of 8535 g and a greatest diameter of 30 cm, the tumor in our patient clearly meets the definition of a giant ovarian teratoma.

3.2. Clinical Presentation

Small mature teratomas are usually asymptomatic and found incidentally. Large tumors, as in our patient, cause obvious symptoms: progressive abdominal distension, pelvic heaviness and chronic abdominopelvic pain, sometimes with menstrual disorders, as observed here. The two-year interval before consultation, in a setting of limited resources and delayed access to imaging, largely explains why the tumor was so large at diagnosis.

3.3. Contribution of Imaging and Tumor Markers

Pelvic ultrasound is the first-line examination for an adnexal mass. CT or magnetic resonance imaging (MRI) is useful when the mass exceeds the ultrasound field of view, as in our patient, to define its relations with adjacent organs. On CT, intratumoral fat, with or without calcification or a Rokitansky nodule, is virtually diagnostic of mature teratoma; MRI with fat-suppressed sequences confirms the fatty component when CT is inconclusive [8]. In our patient, the fat-fluid level and the calcified mural nodule seen on CT strongly suggested a mature teratoma before surgery.

Tumor markers have a limited role in the diagnosis of mature teratoma. Serum CA 19-9 and, to a lesser extent, CA-125 may be moderately raised in dermoid cysts, and their levels tend to increase with tumor size [9]. CA-125 is not specific: it is elevated in many benign conditions, and its main use is in the preoperative assessment of the risk of malignancy of an adnexal mass [10]. In a young woman with a solid-cystic mass, alpha-fetoprotein, β-hCG and lactate dehydrogenase are recommended because raised values suggest a malignant germ cell tumor [10]. Normal values, however, do not exclude an immature teratoma or another malignancy, and the diagnosis rests on histology. In our patient, none of these tests could be performed, which reflects the constraints of hospitals with limited resources.

3.4. Surgical Approach: The Place of Laparotomy

The treatment of mature ovarian teratoma is surgical. Laparoscopy is now a standard tool in gynecological surgery and can be used even for large ovarian cysts, provided that patients are carefully selected and the surgeon is experienced [11].

For very large tumors, however, laparoscopy is limited by the small working space and by a higher risk of intraoperative rupture and spillage of cyst contents [11].

Wang and Li compared single-port laparoscopy, three-port laparoscopy and conventional laparotomy for ovarian cysts larger than 15 cm [11]. Recovery was better after minimally invasive surgery, with no significant difference in major complications. However, these techniques require equipment and expertise that are often lacking in regional hospitals in sub-Saharan Africa.

Given the exceptional size of the tumor and the resources available locally, midline laparotomy was the most appropriate approach in our patient. The same approach was used in most African reports of giant teratomas [5] [6]. Whenever possible, at least part of the healthy ovarian tissue should be preserved, especially in young nulligravid women, in order to protect fertility [12]. In our patient, given the size of the tumor, its adhesions to the ipsilateral tube and the high risk of rupture during an attempted cystectomy, a salpingo-oophorectomy was performed rather than an ovarian cystectomy. This choice, guided by the intraoperative findings, also reduced the risk of rupture and of chemical peritonitis caused by spillage of sebaceous material. If accidental rupture occurs, copious peritoneal lavage with saline is required [12]. Although the contralateral ovary appeared normal at surgery, mature teratomas are bilateral in about 10% - 15% of cases [8]; ultrasound surveillance of the remaining ovary and fertility counseling are therefore important parts of follow-up in this young patient.

3.5. Histology

Pathological examination is the reference standard for confirming mature teratoma and for excluding an immature component or malignant transformation. In our patient, gross and microscopic examination showed tissues derived from several germ layers (skin, mature cartilage and secretory glands) without cytological atypia or malignancy, which is typical of benign mature teratoma.

3.6. Prognosis and Follow-Up

After complete surgical removal, the prognosis of mature ovarian teratoma is generally excellent. The main complications are adnexal torsion, rupture with chemical peritonitis, and compression of adjacent organs by the tumor [2]. Rarer complications have also been reported, such as fistulization of a dermoid cyst into the bladder [13], which shows the range of presentations that may follow prolonged untreated growth.

Malignant transformation is rare but is the most feared complication. It occurs in about 1.5% to 2% of cases, most often as squamous cell carcinoma arising from the skin component [2]. The risk increases with patient age and tumor size [2]. In giant tumors such as the one reported here, the surgical specimen must therefore be examined thoroughly. In our patient, the absence of atypia and malignancy, the uneventful postoperative course and the favorable outcome at six months suggest a good prognosis. Because the tumor was completely excised and histologi-

cally benign, follow-up is not aimed at malignant transformation of the removed lesion. It aims to detect a recurrent or new teratoma in the contralateral ovary, through clinical review, attention to new symptoms such as pelvic pain or abdominal enlargement, and pelvic ultrasound.

3.7. Limitations

This report has limitations. Tumor markers could not be measured, intraoperative frozen section was not available, the presence of residual healthy ovarian tissue on the affected side was not documented in the operative report, and long-term follow-up of ovarian function and fertility is not yet available.

4. Conclusion

Giant mature ovarian teratoma is rare and usually results from delayed diagnosis and limited access to care. Diagnosis is based on clinical examination and imaging, but confirmation is histological. In this patient, laparotomy was appropriate given the size of the tumor and the resources available locally; minimally invasive surgery remains an option for selected patients where equipment and expertise are available. After complete excision of a benign mature teratoma, the prognosis is favorable, and follow-up should focus on the detection of recurrent or contralateral teratoma and of new symptoms.

Consent

Written informed consent was obtained from the patient for the publication of this case report and the accompanying images.

Author Contributions

Moussa Sanogo managed the patient, conceived the report and wrote the first draft. Jean de Dieu Sanou revised the manuscript, reviewed the literature and prepared the English version. Nebon Delphine Bado and Ibrahim Savadogo performed the pathological examination and described the histological findings. Wendwoumyan Judicaël Congo performed and interpreted the imaging. Sansan Rodrigue Sib, P. Rachida M. J. Drabo-Ouédraogo, Azize Tiendrebeogo and Salam Ouédraogo participated in patient care and critically revised the manuscript. Issa Ouédraogo supervised the work.

All authors read and approved the final manuscript.

Conflicts of Interest

The authors declare no conflicts of interest regarding the publication of this paper.

References

[1] Rousseau, M.C. and Demarche, M. (2022) Tératome ovarien chez l'enfant. Revue de la littérature à propos d'un cas clinique. *Revue Médicale de Liège*, **77**, 139-144.

[2] Gadducci, A., Pistolesi, S., Guerrieri, M.E., Cosio, S., Carbone, F.G. and Naccarato, A.G. (2018) Malignant Transformation in Mature Cystic Teratomas of the Ovary: Case Reports and Review of the Literature. *Anticancer Research*, **38**, 3669-3675. https://doi.org/10.21873/anticanres.12644

[3] Barragán-Curiel, A.E., Murillo-Zepeda, C., Castro-Perez, K.F., Alcalá-Aguirre, F.O., Díaz-Montoya, L.S., Ruiz-Félix, O.A., *et al.* (2023) Giant Mature Ovarian Cystic Teratoma in a Pediatric Patient: Case Report and Literature Review. *Case Reports in Oncology*, **16**, 1066-1072. https://doi.org/10.1159/000534141

[4] Lakkis, W.G., Martin, M.C. and Gelfand, M.M. (1985) Benign Cystic Teratoma of the Ovary: A 6-Year Review. *Canadian Journal of Surgery*, **28**, 444-446.

[5] Hounkpatin, B., Dangbemey, D.P., Aboubakar, M., Azonbakin, S., Akodjenou, J., Ogoudjobi, M., *et al.* (2019) Un cas de tératome ovarien mature géant au CHU-MEL de Cotonou (Bénin): Difficultés diagnostiques et qualité de la prise en charge chirurgicale. *Journal Africain de Cas Cliniques et Revues* (*JACCR Africa*), **3**, 431-435.

[6] Ngwe Thaba Moyambe, J., Cham Lubamba, C., Ilunga Nikulu, J., Tamubango Kitoko, H., Isango Idi, Y., Mukendi A Muthsimbe, R., *et al.* (2021) Tératome ovarien mature chez une jeune fille à Lubumbashi, République Démocratique du Congo: À propos d'un cas. *PAMJ Clinical Medicine*, **5**, Article No. 56.

[7] Torabi, H., Shirini, K., Ashoorian, Y. and Ghaffari, R. (2023) A Rare Case of Extremely Large Mature Ovarian Cystic Teratoma. *SAGE Open Medical Case Reports*, **11**. https://doi.org/10.1177/2050313x231159214

[8] Outwater, E.K., Siegelman, E.S. and Hunt, J.L. (2001) Ovarian Teratomas: Tumor Types and Imaging Characteristics. *RadioGraphics*, **21**, 475-490. https://doi.org/10.1148/radiographics.21.2.g01mr09475

[9] Var, T., Tonguc, E.A., Ugur, M., Altinbas, S. and Tokmak, A. (2012) Tumor Markers Panel and Tumor Size of Ovarian Dermoid Tumors in Reproductive Age. *Bratislava Medical Journal*, **113**, 95-98. https://doi.org/10.4149/bll_2012_022

[10] American College of Obstetricians and Gynecologists' Committee on Practice Bulletins-Gynecology (2016) Practice Bulletin No. 174: Evaluation and Management of Adnexal Masses. *Obstetrics & Gynecology*, **128**, e210-e226. https://doi.org/10.1097/AOG.0000000000001768

[11] Wang, X. and Li, Y. (2021) Comparison of Perioperative Outcomes of Single-Port Laparoscopy, Three-Port Laparoscopy and Conventional Laparotomy in Removing Giant Ovarian Cysts Larger than 15 cm. *BMC Surgery*, **21**, Article No. 200. https://doi.org/10.1186/s12893-021-01205-3

[12] Koçak, M., Dilbaz, B., Ozturk, N., Dede, S., Altay, M., Dilbaz, S., *et al.* (2004) Laparoscopic Management of Ovarian Dermoid Cysts: A Review of 47 Cases. *Annals of Saudi Medicine*, **24**, 357-360. https://doi.org/10.5144/0256-4947.2004.357

[13] Rantomalala, H.Y.H., Raveloson, J.R., Rakotoarisoa, B., Rabesata, J.O. and Tovone, X.G. (2003) Une fistulisation vésicale d'un kyste dermoïde de l'ovaire. *Annales d'Urologie*, **37**, 102-104. https://doi.org/10.1016/s0003-4401(03)00035-4