Scientific Research Publishing

Open Journal of Nephrology, 2026, 16(4), 563-569
https://www.scirp.org/journal/ojneph
ISSN Online: 2164-2869
ISSN Print: 2164-2842

Selective Arterial Embolization of Actively Bleeding Large Angiomyolipoma: A Minimally Invasive, Effective, Nephron-Sparing, and Life-Saving Procedure

Kamel El-Reshaid[1*], Shaikha Al-Bader[2], Samer Abou-Deeb[3]

[1]Department of Medicine, Faculty of Medicine, Kuwait University, Kuwait City, Kuwait
[2]Department of Medicine, Nephrology Unit, Jaber Al-Ahmad Hospital, Ministry of Health, Kuwait City, Kuwait
[3]Kuwait + IMAGES Diagnostic Radiology Centre, Kuwait City, Kuwait
Email: *kamel@hsc.edu.kw

How to cite this paper: El-Reshaid, K., Al-Bader, S. and Abou-Deeb, S. (2026) Selective Arterial Embolization of Actively Bleeding Large Angiomyolipoma: A Minimally Invasive, Effective, Nephron-Sparing, and Life-Saving Procedure. *Open Journal of Nephrology*, **16**, 563-569.
https://doi.org/10.4236/ojneph.2026.164048

Received: October 17, 2026
Accepted: November 23, 2026
Published: November 26, 2026

Copyright © 2026 by author(s) and Scientific Research Publishing Inc.
This work is licensed under the Creative Commons Attribution International License (CC BY 4.0).
http://creativecommons.org/licenses/by/4.0/

Open Access

Abstract

Background: Angiomyolipoma (AML) is the most common benign renal tumor. Most are found incidentally on imaging yet are rarely encountered with catastrophic bleeding. The Case: A 54-year-old woman presented with sudden, severe, and progressive left loin pain, followed by collapse 4 hours later. She had no previous illness. On examination, she was afebrile yet hypotensive with a blood pressure of 60/40 and appeared pale. Systemic examination did not show any abnormality except for left loin tenderness. Laboratory investigations were normal except for a hemoglobin level of 40 g/L and elevated serum urea and creatinine. Ultrasound showed a large perinephric hematoma and an echogenic mass. Subsequent CT with contrast and arteriography indicated a bleeding AML and excluded renal and aortic aneurysms and vasculitis. After resuscitation with 8 units of blood, the feeding artery was selectively embolized initially by gelfoam, followed by Embosphere particles and multiple 0.18 detachable microcoils to ensure permanent stasis with limited post-infarction syndrome. Subsequently, she remained clinically stable with a hemoglobin level of 120 g/L and normal kidney function. By 6 weeks, the perinephric hematoma had regressed to minimal streaks. Since the mass was >4 cm and exophytic, it was removed surgically to avoid future bleeding and to rule out cancer. In Conclusion: Life-threatening bleeding is a major risk for large AML > 4 cm. It is amenable to emergency selective arterial embolization followed by elective surgery.

Keywords

Angiomyolipoma, Embolization, Shock, Spontaneous Rupture, Size, Bleed,

Wunderlich Syndrome

1. Introduction

Angiomyolipoma (AML) is the most common benign kidney tumor and was detected in 37 patients from 402 consecutive unselected autopsies (9%) [1]. On abdominal ultrasonography, it has an overall prevalence of 0.44%, with 0.60% in females due to estrogen growth enhancement, though prevalence may be higher based on CT and MRI studies [2]. Histologically, it is a mixture of blood vessels, smooth muscle-like cells, and adipose tissue [2]. AML is usually asymptomatic and found incidentally during kidney imaging for other reasons. Rarely, it can spontaneously rupture, leading to life-threatening retroperitoneal or urinary bleeding called Wunderlich syndrome, which is clinically characterized by Lenk's triad: acute flank pain, a flank mass, and hypovolemic shock [3]. Rupture has been attributed to its pseudoaneurysmal malformation [4]. In our case report, we present a patient with a large occult AML that manifested with severe hypovolemic shock due to internal bleeding that was amenable to emergency selective arterial coil embolization. Diagnosis as well as emergency and definitive management is described.

2. The Case

A 54-year-old woman presented with sudden, severe, and progressive left loin pain followed by collapse 4 hours later. She did not have any previous illness. On examination, she was afebrile yet hypotensive at 60/40 and pale. Systemic examination did not show any abnormality except for left loin tenderness. Laboratory investigations were normal except for hemoglobin at 40 g/L and elevated serum urea and creatinine at 12 mmol/L and 140 μmol/L, respectively. Ultrasound showed a large left perinephric hematoma and an exophytic echogenic solid mass. Subsequent CT with contrast confirmed a large perinephric hematoma (12 × 13 × 25 cm), at its maximum TS, AP, and CC dimensions, extending from D11 down to L5. It was surrounding a fat-containing mass at the anterior pole of the left kidney (**Figure 1(A)**). Two small pseudoaneurysms were noted yet without active contrast extravasation (**Figure 1(B)** & **Figure 2**). Multiple foci of increased density were seen at the upper pole of the hematoma indicating active bleeding (**Figure 1(B)**). After resuscitation with 8 units of blood, embolization of the feeding vessel of the AML was done. The procedure was done under mild sedation and local anaesthesia after informed written consent for the procedure. The right femoral artery was accessed and selective left renal artery catheterization was performed using a 5 Fr C2 catheter. On arteriography, the aorta and main renal vessels did not show aneurysms or vasculitis. Renal arteriogram demonstrated abnormal tortuous tumoral vessels, and its 2 pseudoaneurysms, originating from the anterior pole branch (**Figure 2**). The main feeding branch was superselectively catheter-

ized using a microcatheter and embolization was performed using gelfoam followed by Embosphere particles (300 - 500, 500 - 700, and 700 - 900 microns) and multiple 0.18 detachable micro coils Concerto (three 3 mm × 8 cm and one 4 mm × 10 cm). Final angiogram showed complete stasis of the flow in the angiomyolipoma feeding arterial branch without compromise of its remaining territory perfusion (Figure 3). Subsequently, the patient remained stable clinically with hemoglobin at 120 g/L and normal serum urea and creatinine. By 6 weeks; (a) serological tests for autoimmune disorders and genetic tests were confirmed negative, and (b) CT triphasic showed regression of the perinephric hematoma regressed to minimal streaks yet AML size was 6.6X6.3X7 cm (Figure 4). Since the mass was >4 cm and exophytic; it was removed laparoscopically to avoid future bleed and its histopathological examination confirmed the diagnosis and excluded malignancy (Figure 5).

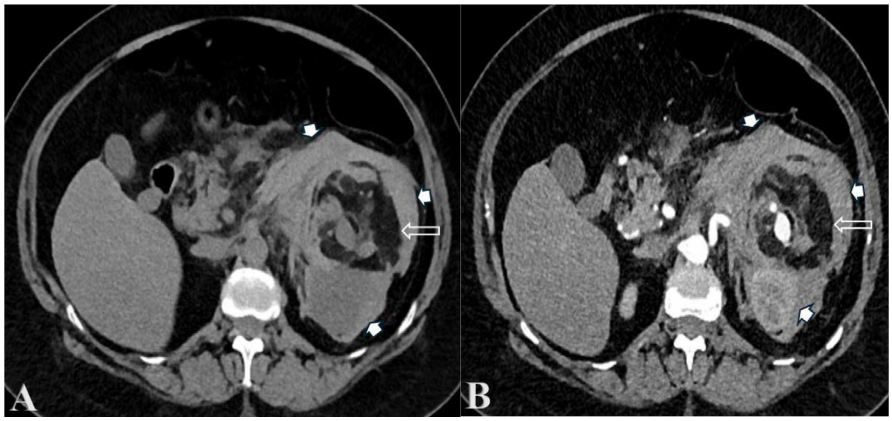

Figure 1. Axial plain (A) and post-contrast arterial phase (B) CT images showing bleeding into a large perinephric hematoma (arrowheads) and the heterogeneous mass with solid and fatty components (open arrow) with its two pseudoaneurysms.



Figure 2. Coronal MIP arterial phase CT image showing the feeding artery of AML with its two aneurysms (arrow).

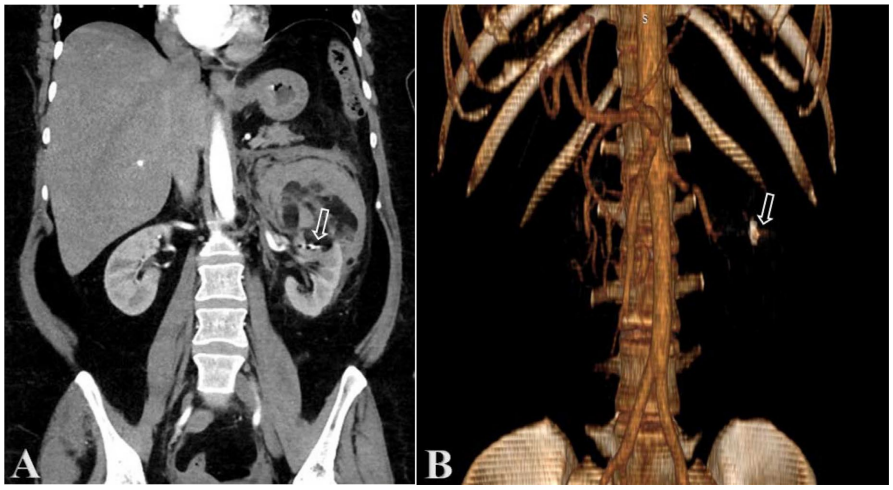

Figure 3. Immediate post-embolization coronal arterial phase CT image (A) and CT 3D reconstruction image (B), showing complete stasis of the flow in the angiomyolipoma feeding arterial branch without compromise of its remaining territory perfusion and with micro-coils in place (arrows).

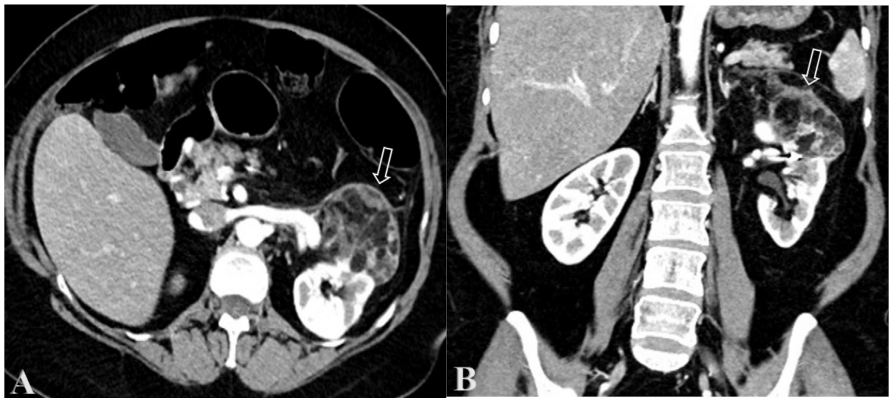

Figure 4. Follow-up contrast-enhanced axial (A) and coronal (B) CT images, 2 months post-embolization, showing minimal perinephric hematoma, moderate volume decrease in the bleeding AML (arrow) without vascular enhancement, and intact remaining kidney tissue.

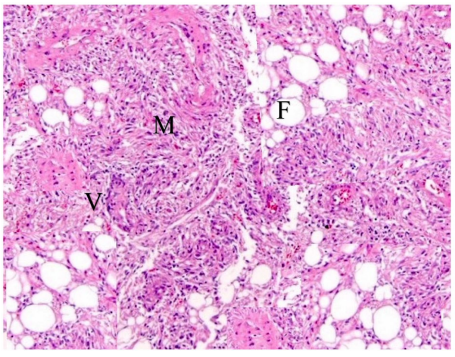

Figure 5. Photomicrograph of the excised kidney mass showing admixture of tortuous thick-walled blood vessels (V), sheets of mature adipose tissue (F) and bundles of smooth muscle fibres (M) (H&E ×100).

3. Discussion

AML is a mesenchymal neoplasm arising from perivascular epithelioid cells [5]. It is composed of an admixture of thick dysmorphic blood vessels, smooth muscle, and adipose tissue with a variable amount of each component, rendering difficulty in radiological diagnosis if there is low fat content and metastasis if it is the epithelioid variant [6] [7]. Nearly 80% of AMLs are unilateral, small, benign, and renal [8]. Non-classic presentation is common in tuberous sclerosis complex (TSC) and pulmonary lymphangioleiomyomatosis, with extrarenal lesions in the liver, lymph nodes, brain, lung, and ovaries [2]. The latter diseases are autosomal dominant disorders due to mutations in one of two genes, TSC1 and TSC2, which encode the proteins hamartin and tuberin, respectively. TSC is caused by mutations in one of two genes, TSC1 and TSC2, which encode the proteins hamartin and tuberin, respectively. These proteins interact with each other to form a tumor suppressor complex, which inhibits the mammalian target of rapamycin (mTOR) pathway. This pathway is important for angiogenesis, protein synthesis, and cell growth. Defective or deficient TSC1 or TSC2 activity leads to unchecked activation of mTOR and the formation of characteristic hamartomas [9]. Hence, the Food and Drug Administration and European Medicines Agency approved lifelong, mTOR inhibitors (Sirolimus and Everolimus) for treating recurrent AML in the setting of TSC [10]. However, their role in sporadic cases remains to be determined. Historically, partial or total nephrectomy was the only elective treatment for large (>4 cm) and actively bleeding cases and for suspicion of malignancy [11]. Recently, selective arterial embolization has evolved as a safe, effective, and nephron-sparing alternative in the setting of large and non-malignant cases, especially prior to conception which promotes its growth [12]. In our patient, we used embosphere particles followed by microcoils. Such management is superior to particulates of polyvinyl alcohol (PVCA) for better control of active bleeding and rebleeding, as well as to restrict the infarcted area, with minimal post-embolization syndrome [13].

4. Conclusion

Non-genetic solitary AML can attain a large size (>4 cm) and can bleed after spontaneous rupture without prior aneurysmal formation. The active bleeding artery can be safely controlled with selective embolization.

Data Sharing Statement

The data that support the findings of this study are available from the corresponding author upon reasonable request.

Author Contributions

Conceptualization & writing (original draft preparation): Kamel El-Reshaid and Shaikha Al-Bader, patient follow up and data collection: Shaikha Al-Bader, Final draft preparation, review and editing: Kamel El-Reshaid, radiological supervision:

Samer Abou-deeb. All authors have read and agreed to the published version of the manuscript.

Conflicts of Interest

The authors declare that they have no potential conflicts of interest related to the contents of this article.

References

[1] Caliò, A., Warfel, K.A. and Eble, J.N. (2016) Pathological Features and Clinical Associations of 58 Small Incidental Angiomyolipomas of the Kidney. *Human Pathology*, **58**, 41-46. https://doi.org/10.1016/j.humpath.2016.07.024

[2] Vos, N. and Oyen, R. (2018) Renal Angiomyolipoma: The Good, the Bad, and the Ugly. *Journal of the Belgian Society of Radiology*, **102**, Article No. 41. https://doi.org/10.5334/jbsr.1536

[3] Shah, J.N., Gandhi, D., Prasad, S.R., Sandhu, P.K., Banker, H., Molina, R., *et al.* (2023) Wunderlich Syndrome: Comprehensive Review of Diagnosis and Management. *RadioGraphics*, **43**, e220172. https://doi.org/10.1148/rg.220172

[4] Mostafa, M.M., Kamel, M., Zarzour, M. and Mahdy, A. (2024) Ruptured Pseudoaneurysm in a Renal Angiomyolipoma: Case Report and Literature Review. *Innovations in Surgery and Interventional Medicine*, **4**, 20-25. https://doi.org/10.36401/isim-24-03

[5] Siroky, B.J., Yin, H., Dixon, B.P., Reichert, R.J., Hellmann, A.R., Ramkumar, T., *et al.* (2014) Evidence for Pericyte Origin of TSC-Associated Renal Angiomyolipomas and Implications for Angiotensin Receptor Inhibition Therapy. *American Journal of Physiology-Renal Physiology*, **307**, F560-F570. https://doi.org/10.1152/ajprenal.00569.2013

[6] Park, B.K. (2017) Renal Angiomyolipoma: Radiologic Classification and Imaging Features According to the Amount of Fat. *American Journal of Roentgenology*, **209**, 826-835. https://doi.org/10.2214/ajr.17.17973

[7] Saoud, R., Kristof, T.W., Judge, C., Chumbalkar, V., Antic, T., Eggener, S., *et al.* (2022) Clinical and Pathological Features of Renal Epithelioid Angiomyolipoma (PEComa): A Single Institution Series. *Urologic Oncology: Seminars and Original Investigations*, **40**, 18-24. https://doi.org/10.1016/j.urolonc.2021.09.010

[8] Fittschen, A., Wendlik, I., Oeztuerk, S., Kratzer, W., Akinli, A.S., Haenle, M.M., *et al.* (2014) Prevalence of Sporadic Renal Angiomyolipoma: A Retrospective Analysis of 61,389 in- and Out-Patients. *Abdominal Imaging*, **39**, 1009-1013. https://doi.org/10.1007/s00261-014-0129-6

[9] Qin, W., Bajaj, V., Malinowska, I., Lu, X., MacConaill, L., Wu, C., *et al.* (2011) Angiomyolipoma Have Common Mutations in TSC2 but No Other Common Genetic Events. *PLOS ONE*, **6**, e24919. https://doi.org/10.1371/journal.pone.0024919

[10] Coombs, E.J. (2013) Role of mTOR Inhibition in the Treatment of Patients with Renal Angiomyolipomas. *Journal of the American Association of Nurse Practitioners*, **25**, 588-596. https://doi.org/10.1002/2327-6924.12081

[11] Ryan, J.W., Farrelly, C. and Geoghegan, T. (2018) What Are the Indications for Prophylactic Embolization of Renal Angiomyolipomas? A Review of the Current Evidence in the Literature. *Canadian Association of Radiologists Journal*, **69**, 236-239. https://doi.org/10.1016/j.carj.2018.01.002

[12] Toei, H., Zhang, X., Seyama, K., Yashiro, D., Kuwatsuru, Y. and Kuwatsuru, R. (2022) Prophylactic Renal Artery Embolization before Pregnancy in Patients with Lymphangioleiomyomatosis and Renal Angiomyolipoma. *Journal of International Medical Research*, **50**. https://doi.org/10.1177/03000605221123897

[13] Xiao, N. and Lewandowski, R.J. (2022) Embolic Agents: Coils. *Seminars in Interventional Radiology*, **39**, 113-118. https://doi.org/10.1055/s-0041-1740939