Scientific Research Publishing

Open Journal of Medical Imaging, 2026, 16(4), 165-170
https://www.scirp.org/journal/ojmi
ISSN Online: 2164-2796
ISSN Print: 2164-2788

Ewing Sarcoma with Spinal and Calvarial Involvement: A Pictorial Essay of an Atypical Presentation

Matheus Cardoso Aragão[1], Daniel Gurgel Fernandes Távora[1,2], Francisco Barbosa de Araújo Neto[1,3], Joao Vitor Lopes Montes[1], Tarsila Stockler Ravaschieri Martinolli[1], Dárvylla de Sousa Lima[1], Antônio Victor Gouveia Azevedo dos Santos[1], Samira Benttenmüller de Freitas[1]

[1]Department of Radiology, Fortaleza General Hospital, Fortaleza, Brazil
[2]Department of Radiology, São Carlos Hospital, Fortaleza, Brazil
[3]Department of Radiology, Uniclinic Diagnostic Imaging, Fortaleza, Brazil
Email: matheuscaragao123@gmail.com

How to cite this paper: Aragão, M.C., Távora, D.G.F., de Araújo Neto, F.B., Montes, J.V.L., Martinolli, T.S.R., de Sousa Lima, D., dos Santos, A.V.G.A. and de Freitas, S.B. (2026) Ewing Sarcoma with Spinal and Calvarial Involvement: A Pictorial Essay of an Atypical Presentation. *Open Journal of Medical Imaging*, **16**, 165-170.
https://doi.org/10.4236/ojmi.2026.164019

Received: September 18, 2026
Accepted: November 20, 2026
Published: November 23, 2026

Copyright © 2026 by author(s) and Scientific Research Publishing Inc.
This work is licensed under the Creative Commons Attribution International License (CC BY 4.0).
http://creativecommons.org/licenses/by/4.0/

Open Access

Abstract

Ewing sarcoma is an aggressive small round cell tumor that mainly affects children and young adults. The pelvis and long bones are the most common sites, whereas extensive disease involving the spine and calvarium is unusual. In such presentations, imaging findings may overlap with those of other infiltrative neoplasms, making the diagnosis challenging. Computed tomography and magnetic resonance imaging are particularly useful for assessing bone involvement, soft-tissue extension, epidural disease, and neural compression, as well as for defining the overall extent of disease. Awareness of these less common patterns may help radiologists raise the appropriate diagnostic suspicion and guide further investigation and management.

Keywords

Ewing Sarcoma, Spine, Calvarium, Imaging Findings, Magnetic Resonance Imaging

1. Introduction

Ewing sarcoma is an aggressive malignant small round cell tumor that predominantly affects children, adolescents, and young adults, with a peak incidence during the second decade of life and a slight male predominance. It is considered the second most common primary malignant bone tumor in this age group. Its estimated incidence is approximately 0.3 cases per 100,000 persons per year [1]. Alt-

hough it may arise throughout the skeleton, the pelvis and long bones are the most frequently involved sites [1]-[4].

Histologically, Ewing sarcoma typically shows sheets of small round cells with scant cytoplasm. CD99 is usually strongly expressed on immunohistochemistry, although this marker is not specific and should not be interpreted in isolation. NKX2.2 is another useful immunohistochemical marker, but, like CD99, it is not entirely specific for Ewing sarcoma [1] [5]. Molecular testing is often useful to support the diagnosis, particularly by demonstrating an EWSR1 rearrangement, most commonly the EWSR1-FLI1 fusion associated with t (11; 22) (q24; q12). Current WHO classification defines Ewing sarcoma by fusions involving EWSR1 or FUS and members of the ETS family of transcription factors [5]. Diagnosis therefore depends on the combined interpretation of morphology, immunohistochemistry, and molecular findings [1] [2] [5] [6].

Clinical presentation varies according to the site and extent of disease. Localized pain and swelling are the most frequent symptoms, while fever, weight loss, and other systemic manifestations may also occur. Ewing sarcoma is characterized by an aggressive biological behavior, and metastatic disease may already be present at diagnosis. The lungs and bones are among the most common sites of distant spread [1] [4] [7] [8].

Imaging is essential for the initial assessment, local staging, detection of metastatic disease, treatment planning, and follow-up. Computed tomography provides detailed evaluation of cortical integrity and osseous destruction, whereas magnetic resonance imaging offers superior characterization of the extent of osseous and soft-tissue involvement and the relationship of the tumor with adjacent neurovascular structures. Systemic staging may additionally include chest CT, PET/CT, or whole-body MRI for the assessment of distant disease [1] [8]. Because imaging findings are not pathognomonic, correlation with clinical, histopathological, and molecular data remains fundamental for diagnosis [1] [2] [5]-[7] [9].

2. Case Presentation

A 25-year-old man reported thoracolumbar pain for approximately two months. The pain progressively worsened and was later accompanied by paresthesias and weakness of the lower limbs. Initial computed tomography and magnetic resonance imaging demonstrated an extensive infiltrative neoplastic process, with relative preservation of the cortical bone, raising suspicion for a lymphoproliferative disorder. Staging CT of the chest, abdomen, and pelvis showed no additional lesions or evidence of another primary malignancy. A calvarial lesion was subsequently biopsied, revealing an undifferentiated small round cell neoplasm. The patient died before a definitive diagnosis could be established and before disease-specific treatment could be initiated. Immunohistochemical analysis, which became available after the patient's death, favored the diagnosis of Ewing sarcoma, with positivity for CD99, NKX2.2, and FLI-1 and negativity for CD45/LCA. Molecular testing for EWSR1 rearrangement or fusion was not performed.

3. Imaging Findings

3.1. Spinal and Epidural Involvement

Spinal disease was extensive, with a long-segment epidural soft-tissue component extending from T12 to S2. This resulted in marked compression of the thecal sac, particularly at L1, L3, L4, L5, and S1, with mild compression of the conus medullaris at T12 and additional left paravertebral extension at L1. The neural foramina were preserved, without evidence of foraminal involvement. In the clinical and imaging context, the spinal involvement was considered the most likely primary site of disease. Figure 1 illustrates the extensive spinal involvement, highlighting the long-segment epidural soft-tissue component and associated compression of the thecal sac.

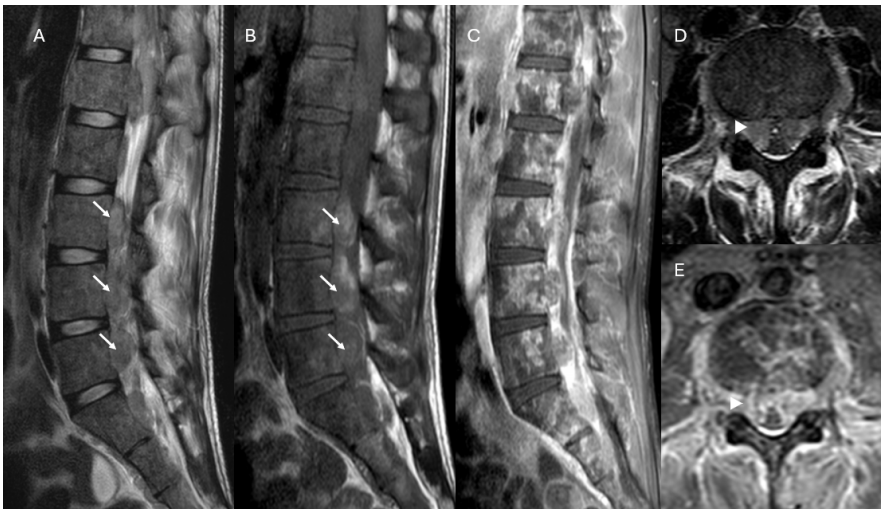

Figure 1. Spinal and epidural involvement in Ewing sarcoma. Sagittal T2-weighted (A) and T1-weighted (B) MR images demonstrate diffuse signal abnormalities involving multiple vertebral bodies, associated with a long-segment epidural soft-tissue component (arrows), resulting in marked compression of the thecal sac. Sagittal post-contrast T1-weighted image (C) demonstrates heterogeneous enhancement of the osseous involvement and epidural component. Axial T2-weighted (D) and post-contrast T1-weighted (E) images confirm the epidural location of the soft-tissue component (arrowheads), with marked compression of the thecal sac.

3.2. Calvarial Involvement

Calvarial involvement was characterized by two expansile lesions centered in the left parietal bone, both associated with prominent epidural and subgaleal soft-tissue components. These lesions were interpreted as metastatic involvement in the setting of the extensive spinal disease, although this distinction could not be definitively established. One of the calvarial lesions was selected for biopsy. Despite the relatively bulky extraosseous extension, the cortical bone was comparatively preserved, an unusual feature that contributed to the initial suspicion of a lymphoproliferative process. Figure 2 demonstrates the calvarial involvement, highlighting the prominent epidural and subgaleal soft-tissue components with rela-

tive preservation of the cortical bone.

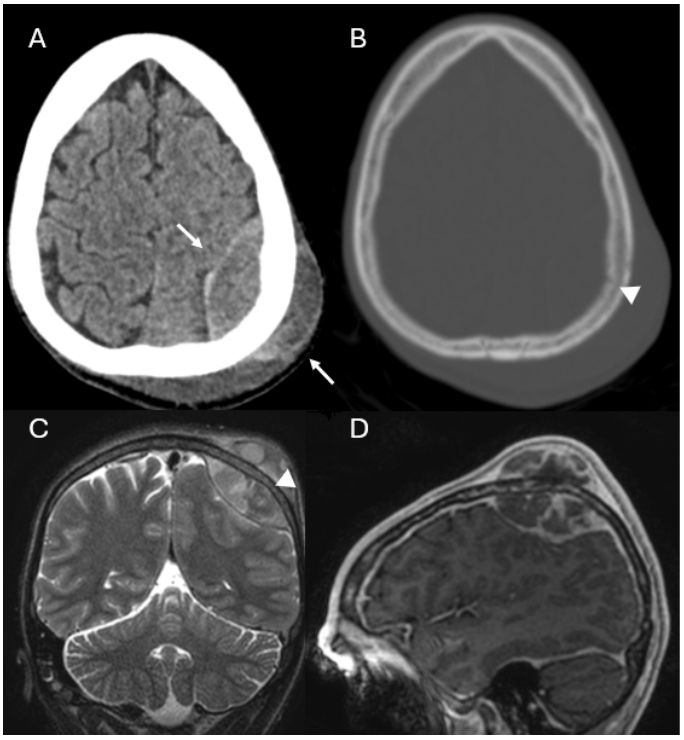

Figure 2. Calvarial involvement in Ewing sarcoma. Computed tomography (A and B) and magnetic resonance imaging (C and D) of the skull. Axial CT image in the soft-tissue window (A) demonstrates an expansile lesion centered in the left parietal calvaria, with epidural and subgaleal soft-tissue components (arrows). Axial CT image in the bone window (B) shows relative preservation of the calvarial cortex despite the bulky extraosseous component (arrowhead). Coronal T2-weighted MR image (C) demonstrates heterogeneous signal intensity of the lesion, with relative preservation of the inner and outer tables (arrowhead). Sagittal post-contrast T1-weighted MR image (D) shows heterogeneous enhancement of the lesion. The lesion shown represents the larger and more prominent of the two left parietal calvarial lesions identified in this patient.

4. Discussion

Ewing sarcoma usually presents as an aggressive bone tumor with a permeative or destructive pattern, frequently associated with a large soft-tissue component. Cortical destruction and adjacent soft-tissue extension are well described. However, rapid infiltrative spread may occasionally occur with little or no cortical disruption, producing a disproportionately large soft-tissue component [1]. Involvement of the axial skeleton is less common than involvement of the pelvis and long bones, and primary involvement of the vertebral column is uncommon, with the sacrum representing the most frequent spinal site [2] [6] [9].

In the spine, Ewing sarcoma may involve the vertebral structures and extend into the epidural or paravertebral spaces. Epidural disease is itself uncommon and may be difficult to distinguish from other neoplastic processes on imaging. In our case, the extensive multilevel epidural involvement, associated with a diffuse in-

filtrative pattern and relatively limited cortical destruction, was not the appearance initially expected for Ewing sarcoma and contributed substantially to the suspicion of a lymphoproliferative disorder. Lymphoma is specifically described among the relevant differential diagnoses of spinal epidural Ewing sarcoma [1] [2] [9].

Calvarial involvement is also uncommon. Reported cases usually describe an aggressive osseous lesion with osteolytic change, cortical destruction, and a relatively large soft-tissue component extending toward the scalp or epidural space. In the series of skull-base lesions reported by Cherekaev *et al.*, computed tomography demonstrated destructive osteolytic changes with irregular osseous defects in all patients. In contrast, the lesions in our case showed prominent epidural and subgaleal extension with comparatively limited cortical destruction, which represented one of the most unusual imaging features [3] [4] [7].

In this case, the combination of extensive infiltrative disease, bulky extraosseous soft-tissue components, multilevel epidural involvement, and relative preservation of the cortical bone initially favored a lymphoproliferative disorder. This overlap illustrates an important diagnostic limitation of imaging: although computed tomography and magnetic resonance imaging accurately demonstrate the distribution and extent of disease, the imaging appearance of Ewing sarcoma is not specific. This diagnostic overlap is also recognized among undifferentiated small round cell sarcomas, in which morphologic and immunohistochemical findings may overlap and molecular testing may be required for definitive classification [5]. Histopathological and immunohistochemical correlation therefore remains essential, while molecular analysis may provide additional confirmation in cases with overlapping morphologic or immunophenotypic features [2] [3] [5] [6].

5. Conclusion

Ewing sarcoma can occasionally present with an infiltrative imaging pattern that differs from its more typical destructive osseous appearance. Recognizing this variability is important, particularly when extensive soft-tissue disease is accompanied by limited cortical destruction, as tissue diagnosis may be required to distinguish it from other infiltrative neoplasms.

Author Contributions

Matheus Cardoso Aragão was responsible for the conceptualization, investigation, and preparation of the original manuscript. Daniel Gurgel Fernandes Távora contributed to the scientific supervision and critical revision of the manuscript. All other authors contributed to the review and editing of the manuscript. All authors have read and approved the final version of the manuscript.

Conflicts of Interest

The authors declare no conflicts of interest regarding the publication of this paper.

References

[1] Mata Fernández, C., Sebio, A., Orcajo Rincón, J., Martín Broto, J., Martín Benlloch, A., Marcilla Plaza, D., *et al.* (2024) Clinical Practice Guidelines for the Treatment of Ewing Sarcoma (Spanish Sarcoma Research Group-GEIS). *Clinical and Translational Oncology*, **27**, 824-836. https://doi.org/10.1007/s12094-024-03602-5

[2] Cherraqi, A., Lemrabet, A., Dokal, I.D., Lrhorfi, N., Belghiti, H., Allali, N., *et al.* (2022) Primary Ewing's Sarcoma of the Spine: About a Case. *Global Pediatric Health*, **9**, 1-5. https://doi.org/10.1177/2333794x221123874

[3] Cherekaev, V.A., Kushel, Y.V., Shkarubo, A.N., Mukhametzhanov, D.J., Stepanyan, M.A., Rotin, D.L. and Vetlova, E.R. (2013) Primary and Metastatic Ewing's Sarcoma of the Skull Base—Case Reports and Comparative Analysis. *Zhurnal Voprosy Neirokhirurgii Imeni N. N. Burdenko*, **77**, 30-36.

[4] Puerta, P., Guillén, A., Mora, J., Suñol, M. and Ferrer, E. (2015) Isolated Skull Metastasis of Ewing's Sarcoma in a Child. *Austin Journal of Cancer and Clinical Research*, **2**, Article 1046.

[5] Dehner, C.A., Lazar, A.J. and Chrisinger, J.S.A. (2024) Updates on WHO Classification for Small Round Cell Tumors: Ewing Sarcoma vs. Everything Else. *Human Pathology*, **147**, 101-113. https://doi.org/10.1016/j.humpath.2024.01.007

[6] Soni, A., Kareem, S.A., Ramachandraiah, M.K., Papanna, A.K.S. and S., V. (2022) Primary Extra-Skeletal Ewing's Sarcoma Presenting as an Epidural Soft Tissue Lesion Causing Cauda Equina Syndrome in an Adolescent Girl: A Case Report. *Spinal Cord Series and Cases*, **8**, Article No. 13. https://doi.org/10.1038/s41394-021-00474-7

[7] Zare, F., Shahbazi, N., Faraji, N., Goli, R., Mostafaei, B. and Anari, S. (2023) A Cruel Invasion of Ewing's Sarcoma of the Skull: A Rare Case Report. *International Journal of Surgery Case Reports*, **108**, Article ID: 108380. https://doi.org/10.1016/j.ijscr.2023.108380

[8] Zöllner, S.K., Amatruda, J.F., Bauer, S., Collaud, S., de Álava, E., DuBois, S.G., *et al.* (2021) Ewing Sarcoma—Diagnosis, Treatment, Clinical Challenges and Future Perspectives. *Journal of Clinical Medicine*, **10**, Article 1685. https://doi.org/10.3390/jcm10081685

[9] Ansari, M.N., Gupta, A., Jain, D.K. and Rana, D. (2022) The Ewing's Sarcoma of Cervical Spine—A Rare Occurrence. *Spinal Cord Series and Cases*, **8**, Article No. 68. https://doi.org/10.1038/s41394-022-00534-6