Open Journal of Depression, 2026, 15(2), 43-51
https://www.scirp.org/journal/ojd
ISSN Online: 2169-9674
ISSN Print: 2169-9658

Bithalamic Infarction Presenting as Postpartum Psychosis: Case Report

Cyrille Duquesne Nkouonlack[1,2*], Clovis Nkoke[1,2], Sylviane Fomekong Dongmo[1,3], Denis George Teuwafeu[1,2], Ronald Mbua Gobina[1,2], Verla Vincent Siysi[1]

[1]Faculty of Health Sciences, University of Buea, Buea, Cameroon
[2]Internal Medicine Department, Buea Regional Hospital, Buea, Cameroon
[3]Medical Imaging Centre, Buea Regional Hospital, Buea, Cameroon
Email: *nkouonlack.dc@ubuea.cm

How to cite this paper: Nkouonlack, C. D., Nkoke, C., Dongmo, S. F., Teuwafeu, D. G., Gobina, R. M., & Siysi, V. V. (2026). Bithalamic Infarction Presenting as Postpartum Psychosis: Case Report. *Open Journal of Depression, 15,* 43-51.
https://doi.org/10.4236/ojd.2026.152003

Received: May 7, 2026
Accepted: May 27, 2026
Published: May 30, 2026

Copyright © 2026 by author(s) and Scientific Research Publishing Inc.
This work is licensed under the Creative Commons Attribution International License (CC BY 4.0).
http://creativecommons.org/licenses/by/4.0/
Open Access

Abstract

Postpartum ischemic stroke associated with acute psychosis is a rare but potentially serious occurrence, with an increased risk in the postpartum period. Bilateral thalamic infarction occurs when the artery of Percheron is occluded and presents vague neuropsychological signs, memory loss, executive dysfunction, and sleeplessness. The association between ischemic stroke and acute psychosis in the postpartum period is rare and has not been described in the literature. We report the case of a 36-year-old woman with no history of psychiatric illness, who presented four weeks postpartum with an acute onset of psychosis with sleeplessness, disorientation, forgetfulness. Brain Magnetic Resonance Imaging (MRI) revealed bilateral thalamic infarction. Although investigations supported thyrotoxicosis as a possible contributor, the exact stroke mechanism in this case remained undetermined mainly due to absence of detailed diagnostic investigations. Treatment with antipsychotics controlled acute psychosis, but speech loss and memory dysfunction persisted. Symptom control of the thyrotoxic phase with beta blockers and secondary prevention of stroke with low-dose aspirin and statins led to symptom improvement. This case highlights the need to consider the evaluation for organic neurological disease in postpartum psychosis and not limited to psychiatric causes. Stroke in the postpartum period may present with nonfocal symptoms, and thus heightened clinical awareness is essential.

Keywords

Thalamus, Psychosis, Stroke, Post-Partum Period

1. Introduction

Pregnancy-related ischemic stroke is an uncommon but potentially serious occur-

rence, with an increased risk in the third trimester and postpartum period due to physiological and pathological factors (Katsafanas & Bushnell, 2022; Miller et al., 2026; Witlin et al., 2000; Yger et al., 2021). Hypercoagulability and hemodynamic changes in circulation and vascular tissue associated with pregnancy account for the increase in neurovascular risk (Miller et al., 2026; Yger et al., 2021). Strategic infarctions involving the arterial blood supply to the thalamus, especially occlusion of an anatomic variant of the paramedian arteries called the Artery of Percheron (AOP), are rare and result in a polymorphism of vascular syndromes (Amin et al., 2011; Morais et al., 2021; Saida et al., 2020). Its presentation with neuropsychiatric manifestations is an uncommon phenomenon, with diagnostic and therapeutic challenges. We report the case of a 36-year-old woman with no previous history of psychiatric disease who presented with acute psychosis as a clinical manifestation of postpartum ischemic stroke four weeks after delivery. Neuroimaging techniques with brain magnetic resonance imaging confirmed the presence of thalamic infarction, and thyroid hormonal analysis indicated thyroiditis. Secondary prevention of infarction with antiplatelet therapy, and other nonspecific therapeutic interventions such as beta-blockers led to improved speech and neuropsychiatric state at one month of follow-up.

2. Patient and Observation

A 36-year-old woman, gravida 4, para 3, with a history of one spontaneous abortion in the first trimester, was brought for neurological consultation due to a sudden onset of difficulty with speech. She has no history of mental illness, and no history of psychiatric disease in previous pregnancies. She was not on oral contraceptives, did not smoke, and denied any history of substance use disorders. She occasionally consumed alcohol during social events. She was the main caregiver to her sick husband during the current pregnancy.

This illness began four weeks after the delivery of her last child; the family noticed a sudden onset of psychomotor agitation, visual hallucinations, and delusions. The husband reported progressive worsening of visual hallucinations and intermittently associated agitation with confusion, orientation deficits, memory loss, sleeplessness, loss of interest in all activities, and neglect of her newborn. These symptoms prompted consultation with a psychiatrist, where a diagnosis of puerperal psychosis was made. Computed tomography (CT) of the brain revealed no acute brain lesions, and her electroencephalogram was normal. No assessment of treatable causes of psychosis, such as acute exacerbations of infectious processes, endocrine, and other autoimmune diseases, was performed. Her treatment consisted of lithium and antipsychotics accompanied by social and family emotional support.

Initial treatment included antipsychotics, and short-term benzodiazepines, with partial remission of psychosis and insomnia. However, the family noticed that she became lethargic, and there was persistent disorientation and memory loss. During her management, she developed a sudden onset of slurred speech,

which prompted consultation at the neurological outpatient clinic.

On physical examination, she had a depressed mood and problems with orientation to the person and time. She had difficulty in the production and comprehension of speech, including naming and repetition. Her vital signs were within normal limits: her blood pressure was 130/82 mmHg, heart rate was 86 beats per minute, respiratory rate was 20 breaths per minute, and she had no fever. Her cognitive performance revealed delayed recall, orientation alterations (MoCA 26/30), and delayed short-term memory and disorientation on the Mini Mental State Examination MMSE (28/30). The Insomnia Severity Index and Pittsburgh Sleep Quality Index revealed no clinically significant insomnia, and the Beck Depression Inventory (BDI) revealed a mild mood disturbance (score of 12). A neurological examination revealed no sensory or motor focal deficits.

Due to the persistent speech deficit of sudden onset, we suspected cerebrovascular disease, and diffusion-weighted magnetic resonance imaging (MRI) of the brain was requested, which revealed infarction of bilateral paramedian thalamic arteries (Figure 1). Random blood sugar (RBS), liver function tests, urea, creatinine, electrolyte test, complete blood count (CBC) and urinalysis were normal. The lipid panel showed low HDL cholesterol (9.8 mg/dl) and elevated triglycerides at 225 mg/dl, total cholesterol (75 mg/dl), and LDL cholesterol (20.2 mg/dl) were normal. As part of the work-up for stroke in a young patient, an electrocardiogram showed sinus tachycardia at 95 beats per minute, a normal axis, and nonspecific repolarization disorders at the septal and apical regions, without atrial fibrillation. The transthoracic echocardiogram was normal, with no evidence of intracardiac thrombus and no cardiac abnormalities such as akinesis or hypokinesis. Carotids and vertebrobasilar arteries vascular imaging, prolonged monitoring, transesophageal echocardiography, and shunt evaluation were not available.

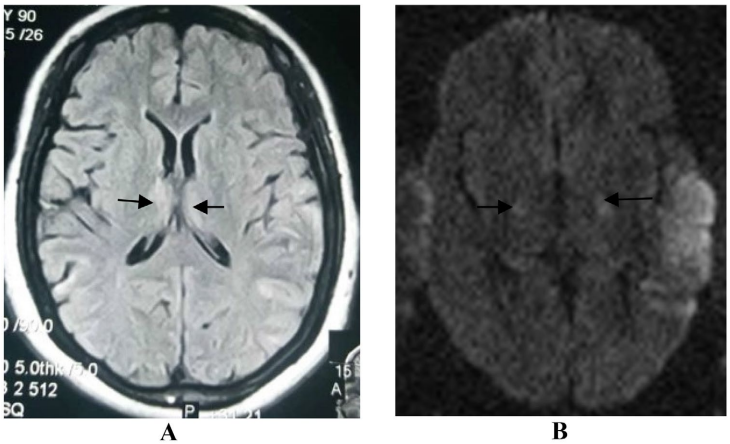

A B

Figure 1. MRI Images of Patient showing acute bilateral thalamic infarction. (A) T2 Flair Sequence of Axial View of the Brain shows the bilateral thalamic high signal intensities (Black Arrows); (B) Diffusion Weighted Image of Brain showing high signal intensity at the bilateral thalami (black arrows).

HIV 1 and 2-serology was negative on the blood specimen. The Treponema

pallidum particle agglutination assay and Venereal Disease Research Laboratory tests were positive in the serum; however, the titer was not reported. This led to the decision to perform a lumbar puncture for Cerebrospinal fluid examination; however, the CSF was negative for TPHA and VDRL, there was no CSF pleocytosis, and all the other parameters of the CSF were within normal limits.

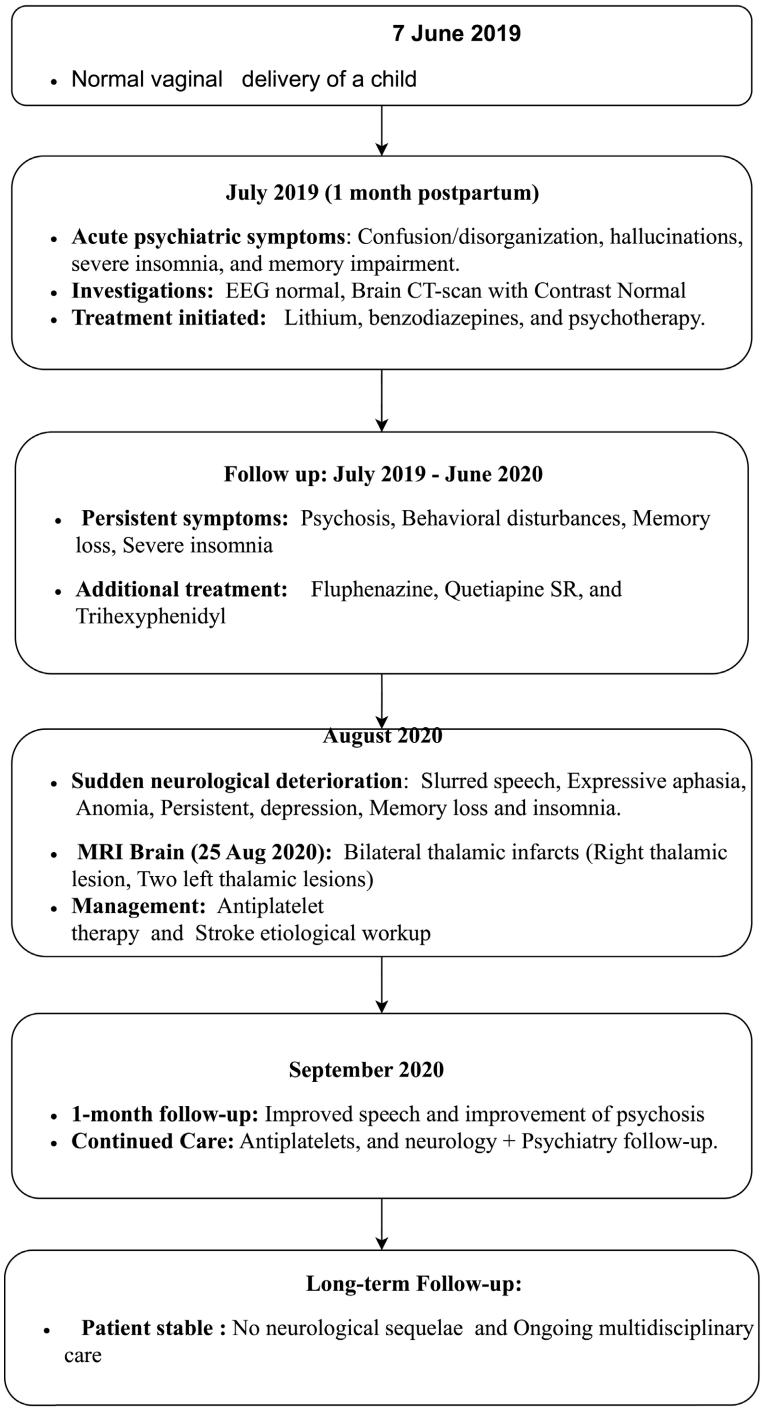

Figure 2. Chronological timeline of postpartum psychosis preceding the diagnosis of bilateral thalamic infarction and subsequent multidisciplinary management.

Thyroid function tests revealed that serum free T3 (triiodothyronine) and free T4 (thyroxin) levels were elevated (8.87 pmol/l and 47.16 pmol/l respectively) and thyroid-stimulating hormone (TSH) levels were low (0.01 μUI/mL). FreeT4 level was higher compared of freeT3 creating a low T3/T4 ratio of 0.188. No thyroid Peroxidase antibodies were administered.

Thrombophilia screening, including protein C activity, protein S, prothrombin time, antithrombin III, homocysteine, and anticardiolipin antibodies, was within the normal range. Antinuclear antibodies were negative.

Given the absence of evidence of cardioembolism, secondary stroke prevention was done with antiplatelet, 100-mg aspirin daily, and statins. Sinus tachycardia and postpartum thyroiditis were treated with propranolol. Antipsychotics gradually tapered off. One month later, the speech deficits had improved, insomnia had resolved completely, and her memory had improved, though with persistent episodes of forgetfulness and some disorientation. She recovered completely from the mood swings, hallucinations, and psychomotor agitation. Her neuropsychological evaluation and higher mental status examination showed normal executive functions, and she returned to work, but there were still delayed recall and orientation problems. Follow-up measurements of the thyroid hormones at one month showed normalized thyroid hormones with levels of Triiodothyronine (Free T3) at 2.66 pmol/L, Thyroxine (free T4) at 10.16 pmol/L and TSH levels at 4.92 μUI/L respectively. **Figure 2** shows the chronological timeline of the events from delivery, and postpartum psychosis preceding the diagnosis of bilateral thalamic infarction and subsequent multidisciplinary management.

3. Discussion

This case report concerns a rare presentation of acute psychosis due to postpartum ischemic stroke with diagnostic and therapeutic challenges. Psychosis in the postpartum period is uncommon, with an incidence range from 0.89 and 2.6 in 1000 births and leads to serious perinatal morbidity (Castro et al., 2014; VanderKruik et al., 2017). Acute psychosis occurring in the postpartum period can have a confounding range of etiologies ranging from neurological, systemic, or drug-induced, and not only due to postpartum psychosis. A first-onset acute psychosis in the postpartum period, as in this case report, can either be an isolated postpartum psychosis or an expression of bipolar mood disorders, therefore, the assessment of such patients should include a search for non-psychiatric and treatable causes of psychosis (Bergink et al., 2016).

Cerebrovascular disease coexisting with postpartum psychosis is poorly appreciated, and the diagnosis is delayed because it occurs in a minority of cases (Michalczyk et al., 2023). Our patient presented with signs of psychosis, memory loss, and sleeplessness. She had no localized neurological features suggestive of classic signs of stroke, leading to a delay in diagnosis and management. Due to the increased risk of stroke in the postpartum period and its atypical presentation with syndromes, such as acute psychosis (Miller et al., 2016, 2026; Yger et al., 2021), it

is imperative to have a high index of suspicion of stroke in this context.

The mechanism of stroke was undetermined. The etiologic diagnosis and mechanism of stroke in our patient remained a challenge, due to limitations in diagnostic tools such as prolonged monitoring, shunt evaluation, and transesophageal echocardiography as mentioned above. In pregnancy-associated ischemic stroke, in addition to classical risk factors such as hypertension, diabetes, smoking, and dyslipidemia, other etiologic factors such as peripartum cardiomyopathy, post-partum cerebral angiopathy, preeclampsia/eclampsia, and amniotic fluid embolism have been described (Katsafanas & Bushnell, 2022; Kremer et al., 2022; Miller et al., 2016). However, our patient had none of the above clinical presentations, and the investigations were not exhaustive. It is therefore challenging to determine the exact mechanism of stroke in our patient, whether it was due to cardioembolism or small artery disease.

The presentation of acute psychosis and speech deficits associated with thalamic infarction on brain MRI can provide clues as to the mechanism of stroke in our patient. Thalamic infarction can lead to wide variations in nonspecific neurological presentations, with mental status changes, behavior, and memory impairment being the most common neuropsychological features (Adoukonou et al., 2020; Chen et al., 2021; Khanni et al., 2018), because the thalamus plays a significant role in several brain functions, such as memory, emotions, and the sleep-wake cycle (Khanni et al., 2018). Bilateral paramedian thalamic infarction is observed when the Artery of Percheron is occluded, and its most reported etiologies are small artery disease and cardioembolism (Kichloo et al., 2019; Rodriguez & Lee, 2013). This patient had no pre-existing medical conditions, such as diabetes, hypertension, heart disease, thrombophilia, antiphospholipid syndrome, or endocrine illness, which increased the risk of stroke. She had no pregnancy-related complications, such as preeclampsia/eclampsia or post-partum hemorrhage, which increased the risk of pregnancy-related stroke.

The only classical modifiable risk factor for stroke is dyslipidemia, with elevated triglyceride levels. Electrocardiography revealed no signs of atrial fibrillation. We did not test further for cardioembolism in our patient, which is a limitation as some of the etiologies of cryptogenic stroke which can be seen only after carotids and vertebrobasilar arteries vascular imaging, prolonged Holter ECG monitoring, transesophageal echocardiography, and shunt evaluation were not available.

The ratio of free T3 to free T4 in our patient was low at 0.188, and a low ratio as such supports a diagnosis of sub-acute thyroiditis in the postpartum period (Tingi et al., 2016). Therefore, it is possible that our patient had a sudden change in thyroid function that could be responsible for the mental state changes observed in our patient, as the thyrotoxicosis phase of postpartum thyroiditis can be associated with acute psychosis. This data supports thyrotoxicosis as a possible contributor, however, there is no confirmation that it was the mechanism of stroke in this case.

Other possible etiologies of stroke in young adults in our setting include infec-

tious causes such as chlamydia pneumonia, HIV infection, and neurosyphilis, which is a form of meningitis involving vasculitis of small and medium-sized arteries such as the artery of Percheron in the thalamus, which can cause stroke in young patients (Miller et al., 2016; Rodriguez & Lee, 2013; Witlin et al., 2000) The patient had a positive Treponema Pallidum particle agglutination assay and Venereal Disease Research Laboratory tests in the serum, but there was no pleocytosis in the cerebrospinal fluid, and the CSF VDRL test was not reactive. The laboratory diagnosis of neurosyphilis is based on abnormal serum and CSF serologic tests and elevated CSF white cell count and protein levels, which was not the case in this patient. An unspecific clinical syndrome such as acute postpartum psychosis is consistent with neurosyphilis, but a nonreactive CSF treponemal test makes the diagnosis of neurosyphilis unlikely. The diagnosis of meningovascular syphilis was a possible cause of psychosis and ischemic infarction, however, the CSF analysis was negative. The diagnosis of meningovascular syphilis remains a challenge as it can mimic other diseases, but its diagnosis requires the presence of a positive CSF analysis (Kuma et al., 2024). It is not known if our patient had had prior treatment for syphilis.

The mechanisms and causes of stroke in the postpartum period are multifactorial. Another diagnostic challenge of this case is that we did not formally exclude causes such as cerebral venous thrombosis and reversible cerebral vasoconstriction syndrome. Hemodynamic changes and hypercoagulable state are possible causes of cerebrovascular complications during postpartum that should be investigated and treated to improve outcomes (Katsafanas & Bushnell, 2022; Kremer et al., 2022; Miller et al., 2026).

Before consultation with a neurologist, the pharmacological management of the patient consisted of short-term benzodiazepines, and antipsychotics. This therapeutic regimen improves sleep quality and controls acute psychosis. Memory loss and expressive aphasia caused by ischemic stroke led to a presumptive etiological diagnosis of small artery disease, and she was started on low-dose aspirin (100 mg daily). Sinus tachycardia due to thyrotoxicosis of the postpartum thyroiditis was managed with the beta blocker propranolol, with substantial improvement of symptoms in the patient. The complete resolution of psychosis and the normalization of thyroid hormone at one month of follow-up are in favour of a transient thyrotoxicosis phase in postpartum thyroiditis, although we cannot ascertain that it was the etiology of the infarction. She had persistent delayed recall on memory tests, and alterations in orientation sequelae to the thalamic infarction.

4. Conclusion

The occurrence of acute postpartum psychosis, though more prevalent in genetically predisposed women with multiple physiological triggers such as hormonal, immunological, and circadian rhythm risk factors, can be related to specific organic etiologies. However, its association with cerebrovascular is rare. Non-psychiatric symptoms such as disorientation, forgetfulness, and speech problems in

patients with postpartum psychosis can be a sign of underlying neurological disease like an ischemic stroke, and not purely psychological. This suggests a need for a broader differential diagnosis considering organic neurological disease and prompt neuroimaging, even in the absence of classical stroke signs.

Ethical Compliance

All procedures involved in the drafting of this case report were in accordance with the ethical standards of the institutional and/or national research committee and with the 1964 Helsinki Declaration and its later amendments or comparable ethical standards. A written informed consent form was obtained from the participant.

Conflicts of Interest

The authors declare no conflict of interest.

References

Adoukonou, T., Agbétou, M., Kaboré, R., Faugeras, F., Macian-Montoro, F., Vallat, J. et al. (2020). Bithalamic Infarct Revisited: Clinical, Imaging, Neuropsychological Profile and Prognosis. *Clinical Neurology and Neuroscience, 4,* Article 44. https://doi.org/10.11648/j.cnn.20200403.11

Amin, O. S. M., Shwani, S. S., Zangana, H. M., Hussein, E. M. H., & Ameen, N. A. (2011). Bilateral Infarction of Paramedian Thalami: A Report of Two Cases of Artery of Percheron Occlusion and Review of the Literature. *BMJ Case Reports, 2011,* bcr0920103304. https://doi.org/10.1136/bcr.09.2010.3304

Bergink, V., Rasgon, N., & Wisner, K. L. (2016). Postpartum Psychosis: Madness, Mania, and Melancholia in Motherhood. *American Journal of Psychiatry, 173,* 1179-1188. https://doi.org/10.1176/appi.ajp.2016.16040454

Castro, J., Billick, S., Kleiman, A., Chiechi, M., & Al-Rashdan, M. (2014). Confounding Psychosis in the Postpartum Period. *Psychiatric Quarterly, 85,* 91-96. https://doi.org/10.1007/s11126-013-9271-5

Chen, P., Hao, M. -M., Chen, Y., Zhang, H., Wang, Z., Zhao, B. et al. (2021). Clinical Analysis of Bilateral Thalamic Infarction Caused by Percheron Artery Occlusion. *Neuropsychiatric Disease and Treatment, 17,* 1707-1712. https://doi.org/10.2147/ndt.s296685

Katsafanas, C., & Bushnell, C. (2022). Pregnancy and Stroke Risk in Women. *Neurobiology of Disease, 169,* Article 105735. https://doi.org/10.1016/j.nbd.2022.105735

Khanni, J. L., Casale, J. A., Koek, A. Y., Espinosa del Pozo, P. H., & Espinosa, P. S. (2018). Artery of Percheron Infarct: An Acute Diagnostic Challenge with a Spectrum of Clinical Presentations. *Cureus, 10,* e3276. https://doi.org/10.7759/cureus.3276

Kichloo, A., Jamal, S. M., Zain, E. -A., Wani, F., & Vipparala, N. (2019). Artery of Percheron Infarction: A Short Review. *Journal of Investigative Medicine High Impact Case Reports, 7,* 1-6. https://doi.org/10.1177/2324709619867355

Kremer, C., Gdovinova, Z., Bejot, Y., Heldner, M. R., Zuurbier, S., Walter, S. et al. (2022). European Stroke Organisation Guidelines on Stroke in Women: Management of Menopause, Pregnancy and Postpartum. *European Stroke Journal, 7,* 1-19. https://doi.org/10.1177/23969873221078696

Kuma, A., Tadesse, S. A., & Girma, A. (2024). Meningovascular Syphilis Presenting as

Acute Ischemic Stroke in an HIV + Young Adult: A Case Report and a Brief Literature Review. *International Medical Case Reports Journal, 17,* 581-586. https://doi.org/10.2147/imcrj.s455675

Michalczyk, J., Miłosz, A., & Soroka, E. (2023). Postpartum Psychosis: A Review of Risk Factors, Clinical Picture, Management, Prevention, and Psychosocial Determinants. *Medical Science Monitor, 29,* e942520-1-e942520-13. https://doi.org/10.12659/msm.942520

Miller, E. C., Bello, N. A., Chen, P. R., Leffert, L., Leppert, M., Madsen, T. et al. (2026). Prevention and Treatment of Maternal Stroke in Pregnancy and Postpartum: A Scientific Statement from the American Heart Association. *Stroke, 57,* e127-e145. https://doi.org/10.1161/str.0000000000000514

Miller, E. C., Yaghi, S., Boehme, A. K., Willey, J. Z., Elkind, M. S. V., & Marshall, R. S. (2016). Mechanisms and Outcomes of Stroke during Pregnancy and the Postpartum Period. *Neurology Clinical Practice, 6,* 29-39. https://doi.org/10.1212/cpj.0000000000000214

Morais, J., Oliveira, A. A., Burmester, I., & Pires, O. (2021). Artery of Percheron Infarct: A Diagnostic Challenge. *BMJ Case Reports, 14,* e236189. https://doi.org/10.1136/bcr-2020-236189

Rodriguez, E. G., & Lee, J. A. (2013). Bilateral Thalamic Infarcts Due to Occlusion of the Artery of Percheron and Discussion of the Differential Diagnosis of Bilateral Thalamic Lesions. *Journal of Radiology Case Reports, 7,* 7-14. https://doi.org/10.3941/jrcr.v7i7.961

Saida, I. B., Saad, H. B., Zghidi, M., Ennouri, E., Ettoumi, R., & Boussarsar, M. (2020). Artery of Percheron Stroke as an Unusual Cause of Hypersomnia: A Case Series and a Short Literature Review. *American Journal of Men's Health, 14,* 1-10. https://doi.org/10.1177/1557988320938946

Tingi, E., Syed, A. A., Kyriacou, A., Mastorakos, G., & Kyriacou, A. (2016). Benign Thyroid Disease in Pregnancy: A State of the Art Review. *Journal of Clinical & Translational Endocrinology, 6,* 37-49. https://doi.org/10.1016/j.jcte.2016.11.001

VanderKruik, R., Barreix, M., Chou, D., Allen, T., Say, L., & Cohen, L. S. (2017). The Global Prevalence of Postpartum Psychosis: A Systematic Review. *BMC Psychiatry, 17,* Article No. 272. https://doi.org/10.1186/s12888-017-1427-7

Witlin, A. G., Mattar, F., & Sibai, B. M. (2000). Postpartum Stroke: A Twenty-Year Experience. *American Journal of Obstetrics and Gynecology, 183,* 83-88. https://doi.org/10.1016/s0002-9378(00)70397-8

Yger, M., Weisenburger-Lile, D., & Alamowitch, S. (2021). Cerebrovascular Events during Pregnancy and Puerperium. *Revue Neurologique, 177,* 203-214. https://doi.org/10.1016/j.neurol.2021.02.001