Scientific Research Publishing

Open Journal of Anesthesiology, 2026, 16(11), 183-195
https://www.scirp.org/journal/ojanes
ISSN Online: 2164-5558
ISSN Print: 2164-5531

Arterial Line Pressure Topography as the First Sign of Acute Type A Aortic Dissection during Veno-Arterial Extracorporeal Membrane Oxygenation after Aortic Valve Replacement: A Case Report

Ji Young Park, Eugene Kim, Min Sun Park, Ji Young Yoo*

Department of Anesthesiology and Pain Medicine, Ajou University School of Medicine, Suwon, Korea
Email: *anesyoo@ajou.ac.kr

How to cite this paper: Park, J.Y., Kim, E., Park, M.S. and Yoo, J.Y. (2026) Arterial Line Pressure Topography as the First Sign of Acute Type A Aortic Dissection during Veno-Arterial Extracorporeal Membrane Oxygenation after Aortic Valve Replacement: A Case Report. *Open Journal of Anesthesiology*, **16**, 183-195.
https://doi.org/10.4236/ojanes.2026.1611017

Received: October 12, 2026
Accepted: November 24, 2026
Published: November 27, 2026

Copyright © 2026 by author(s) and Scientific Research Publishing Inc.
This work is licensed under the Creative Commons Attribution International License (CC BY 4.0).
http://creativecommons.org/licenses/by/4.0/

Open Access

Abstract

Background: Veno-arterial extracorporeal membrane oxygenation (VA-ECMO) is widely used for post-cardiotomy cardiogenic shock. The variables on the ECMO console describe circuit function, not regional tissue perfusion, and where an aortic dissection is present, retrograde femoral perfusion may accompany branch-vessel malperfusion while every console variable remains unchanged. **Case Presentation:** A 73-year-old man underwent aortic valve replacement for severe calcific aortic stenosis. Preoperative computed tomography showed no dissection, and transoesophageal echocardiography (TEE) before and immediately after bypass showed no intimal flap. Separation from bypass was uneventful, but after chest closure, a ventricular tachyarrhythmia, progressive hypoxaemia and vasopressor-dependent shock developed, and peripheral VA-ECMO was established through the left femoral vessels at 4.0 L/min. Two arterial sites had been monitored from induction. Ten minutes after support began, with circuit flow unchanged, the right femoral pressure fell to 17 - 20 mmHg while the left radial pressure remained 72/66 mmHg, and the patient was transferred to the intensive care unit on that basis. Within 25 minutes, neither line produced a waveform; a third line, placed in the right upper limb at 15:36, read normally. A blood gas at that point showed a normal pH of 7.390 with a base excess of −9.3 mmol/L and a lactate of 7.0 mmol/L. TEE then showed an aortic flap, and computed tomographic angiography demonstrated acute type A dissection extending to both external iliac arteries, involving the left common carotid and left subclavian arteries, with dynamic obstruction of the left renal and right iliac arteries. The topography of the monitored sites corresponded to

that branch-vessel map. Aortic fenestration with renal and iliac stenting was performed, but coagulopathic haemorrhage supervened and the patient died early the following morning. **Conclusion:** In this patient, regional arterial pressure discordance was the first finding that pointed to a vascular cause of deterioration, at a time when circuit flow was unchanged, the upper-limb pressure was preserved and the arterial pH was normal. A single case cannot establish the diagnostic performance of this sign, and we report the observation as hypothesis-generating.

Keywords

Aortic Dissection, Extracorporeal Membrane Oxygenation, Malperfusion, Arterial Pressure Monitoring, Base Excess

1. Introduction

Acute aortic dissection complicating cardiac surgery is uncommon but highly lethal: iatrogenic type A dissection has been reported to complicate 0.06% of cardiac surgical procedures, with an early mortality of 41.7% [1]. Malperfusion is common once dissection is established and carries a graded mortality penalty; in the GERAADA registry of 2137 patients operated for acute type A dissection, 717 (33.6%) had pre-operative malperfusion, and 30-day mortality rose from 12.6% when no organ system was affected to 43.4% when three were [2]. Recognition in the early postoperative period is confounded by the many other causes of shock in that setting.

Veno-arterial extracorporeal membrane oxygenation is now routine for post-cardiotomy cardiogenic shock, and peripheral femoral cannulation is the configuration achieved most rapidly [3]. Retrograde femoral return, however, interacts with aortic pathology in ways that have no counterpart in antegrade native circulation. The console reports pump speed, circuit flow and line pressures, which describe the circuit rather than the patient; a dissection flap may convert a fully supported circulation into regional malperfusion without altering a single displayed number.

We report a patient in whom acute type A aortic dissection after aortic valve replacement first pointed to a vascular cause through discordance between arterial pressure sites, and in whom the spatial pattern of that discordance corresponded to the branch-vessel anatomy later shown on computed tomography. We describe which monitored variables misled and which did not, and the therapeutic conflict that followed. These are the observations of a single case and are offered as hypothesis-generating rather than as evidence of a validated diagnostic sign.

2. Case Presentation

This report follows the CARE reporting guideline [4].

2.1. Preoperative Assessment

A 73-year-old man (78 kg, 166 cm) with hypertension, diabetes and previously treated prostate cancer presented with severe calcific aortic stenosis and moderate aortic regurgitation. Peak aortic velocity was 4.3 m/s, mean gradient 48 mmHg, ejection fraction 42%, left ventricular end-diastolic dimension 66 mm, mass index 171.7 g/m^2, mean E/E' 18.8 and global longitudinal strain −12.2%. Computed tomography showed a valve calcium score of 1989 and a mildly dilated ascending aorta of 40.3 mm, with no dissection. Coronary angiography showed no significant obstructive disease.

2.2. Operation

Arterial pressure was monitored from induction at two sites—the left radial and right femoral arteries. Through a median sternotomy, arterial cannulation was performed in the ascending aorta. The operating surgeon reported that a straight-tip cannula was used at the usual transition between the ascending aorta and the lesser curvature, but that in this patient it was advanced somewhat deeper than his customary position. Bypass ran 129 minutes with a cross-clamp time of 114 minutes. The valve was tricuspid with annular calcification; because the calcification was severe, the surgeon reported that decalcification was carried out deeply in the region of the non-coronary cusp. A 25 mm tissue valve was implanted. The aortotomy was closed with a pericardial patch for reinforcement and the suture line was sealed with surgical glue. The pleural spaces were not opened. TEE before bypass and immediately after separation showed no intimal flap.

2.3. Deterioration after Chest Closure

Separation from bypass was uneventful and required only low-dose norepinephrine, with no arrhythmia. After chest closure, a narrow-complex tachycardia of suspected junctional origin was followed by ventricular tachycardia, treated with lidocaine 100 mg and cardioversion at 100 J then 150 J. A recurrent tachycardia followed in which adenosine produced no effect; amiodarone 150 mg was given twice with an infusion of 60 mg/h and concurrent pacing. Over the same period, the PaO_2/FiO_2 ratio fell from 221 at 12:18 to 68 at 13:48. No rhythm tracings from this period were retained, so the arrhythmias are reported as diagnosed clinically at the time.

2.4. Extracorporeal Support and Pressure Discordance

At 14:40, VA-ECMO was established through the left femoral vessels at 4.0 L/min, with a mean arterial pressure of 60 - 70 mmHg. At 14:50, with flow unchanged at 4.0 L/min, the right femoral pressure fell to 20, then 19, then 17 mmHg while the left radial pressure remained 72/66 mmHg. Because circuit flow was maintained and the upper-limb pressure preserved, this was not taken at the time as evidence of a structural problem, and the patient was transferred to the intensive care unit. The record does not document whether aortic dissection or branch-vessel malperfu-

sion was considered during this interval.

On arrival at 15:10, neither of the two original lines produced a waveform. The patient had just been moved between beds and transferred from the operating room monitor to the intensive care unit monitor, and equipment malfunction was suspected first: replacement monitoring equipment was requested and brought to the bedside, and both lines were re-tested on the substituted equipment. No waveform returned at either site, and by 15:15 the left radial pressure was recorded as lost. Obtaining the echocardiography machine took further time. These steps account for much of the interval between the first pressure discrepancy and the transoesophageal study. The record does not itemise which individual components were re-zeroed, flushed or exchanged. At 15:20, non-invasive pressure in the right upper limb was 151/93 mmHg with carotid pulsation present, and a new right upper-limb arterial line placed at 15:36 read normally. A blood gas at 15:30 showed pH 7.390, pCO_2 23.2 mmHg, PaO_2/FiO_2 684 and saturation 99.9%, with base excess −9.3 mmol/L, bicarbonate 14.2 mmol/L and lactate 7.0 mmol/L—against −5.2, 19.3 and 1.5 at 13:48 (**Figure 1**).

2.5. Diagnosis

TEE at 15:46 showed an aortic flap; at 15:55, the chest drain yielded 1300 mL of blood. Computed tomographic angiography at 16:33 described acute type A dissection extending to both external iliac arteries, dynamic obstruction of the left renal and right iliac arteries, involvement of the left common carotid and left subclavian arteries, origin of the superior mesenteric, right renal and inferior mesenteric arteries from the true lumen, and bilateral haemothorax (**Figure 2**). The site of the primary intimal tear was not localised. The report did not describe the innominate artery, and did not comment on the aortic root or the coronary ostia. The contemporaneous progress note recorded absent lower limb pulses and absent lower limb perfusion; fenestration was planned with interventional radiology to restore perfusion and to prevent spinal cord ischaemia.

2.6. Reperfusion, Haemorrhage and Outcome

Aortic fenestration with left renal and iliac stenting was performed between 17:55 and 19:30, with transfusion of packed cells, fresh frozen plasma and apheresis platelets. From 19:33, the pressure fell to 52/49 mmHg with heavy chest drainage, and a gas at 20:44 showed pH 6.984, base excess −23.1 mmol/L, lactate 16.9 mmol/L and haemoglobin 8.9 g/dL. At exploratory thoracotomy at 20:45, no active bleeding site was identified: the haematoma was modest and the record describes diffuse oozing attributed to disseminated intravascular coagulation, treated with topical sealant. The coagulation studies were concordant with that attribution. On admission, the prothrombin time was 13.4 s and the activated partial thromboplastin time 35 s, both within the reference range. At 15:27 - 47 minutes after extracorporeal support began, before the transoesophageal study and before fenestration—the prothrombin time was 36.9 s, the activated partial thromboplastin

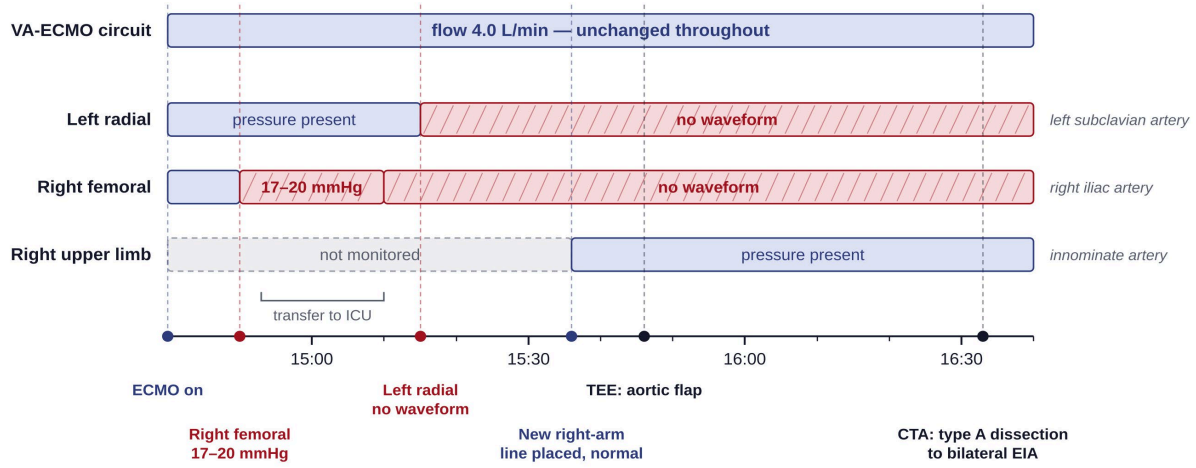

Figure 1. Timeline of extracorporeal support and arterial pressure at the monitored sites, from initiation of VA-ECMO to the imaging diagnosis. Circuit flow was unchanged at 4.0 L/min throughout. The left radial and right femoral lines were in place from induction; the right upper-limb line was placed at 15:36.

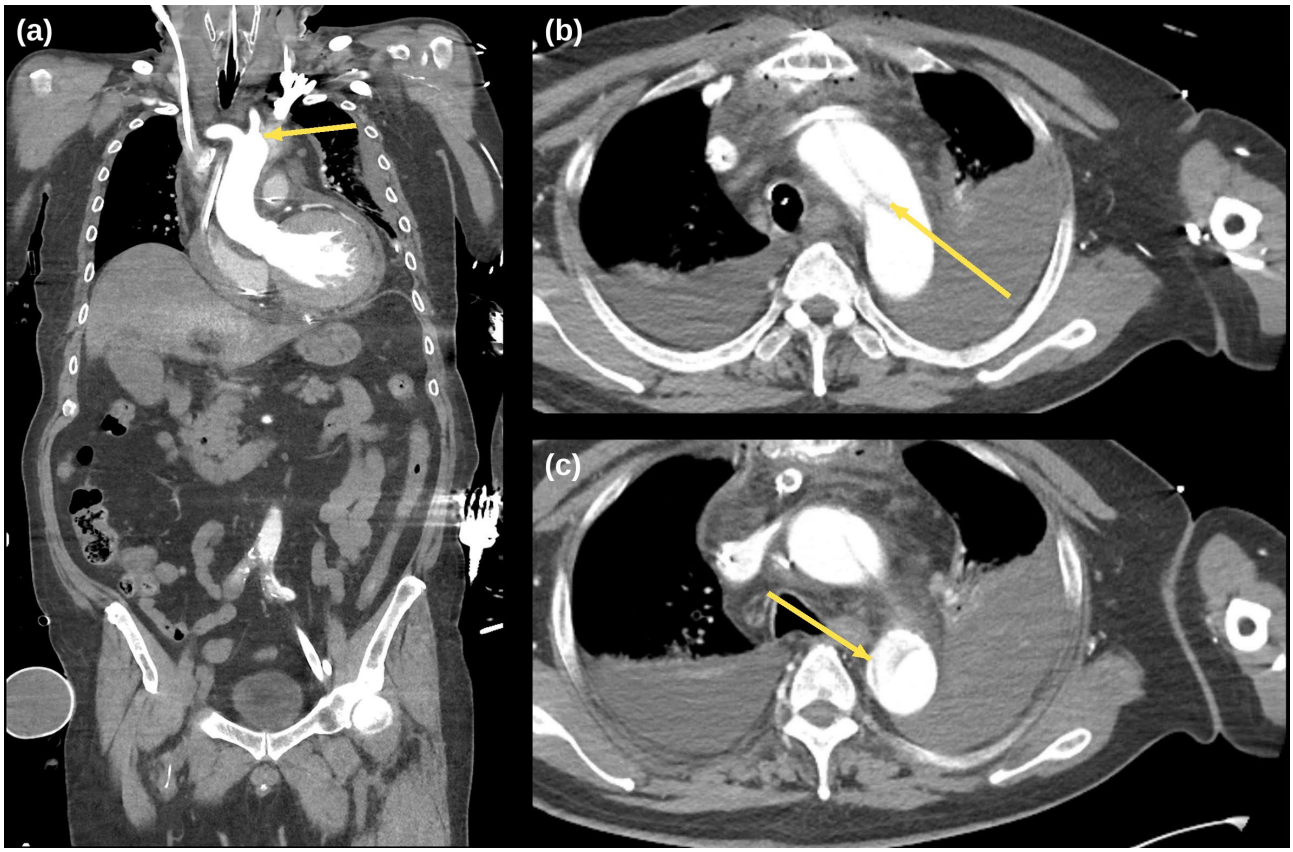

Figure 2. Computed tomographic angiography. (a) Oblique coronal reconstruction through the ascending aorta and aortic arch: soft-tissue density consistent with mediastinal haematoma lies adjacent to the arch, behind the origin of the innominate artery (arrow). (b) Axial image at the level of the aortic arch—the segment from which the left common carotid and left subclavian arteries arise, both reported as involved; an intimal flap traverses the arch lumen (arrow). (c) Axial image at the level of the descending thoracic aorta: an intimal flap (arrow) separates an opacified true lumen from a less opacified false lumen. Mediastinal soft-tissue change and bilateral pleural collections are present. The site of the entry tear was not localised on imaging.

time was at the upper reportable limit of 180 s, the fibrinogen was 72 mg/dL (reference range 182 - 380), the D-dimer was 1.06 μg/mL (reference ≤0.50) and fibrin degradation products were 5.5 μg/mL (reference ≤5.0). By 23:29, the prothrombin time was 49.6 s and the fibrinogen 46 mg/dL. Heparin prolongs the activated partial thromboplastin time and, to a lesser degree, the prothrombin time, and the patient was anticoagulated for the circuit; the fibrinogen concentrations are not attributable to heparin. The platelet count from this period was not retrievable, so a formal International Society on Thrombosis and Haemostasis score was not assigned, although the available components—a prothrombin time prolonged by more than 6 s, a fibrinogen below 100 mg/dL and a fibrin marker above the reference range—are each consistent with overt disseminated intravascular coagulation. Cumulative chest tube drainage was approximately 4200 mL and urine output fell from 1570 mL to 170 mL between recorded intervals.

At the same operation, the surgical team judged that retrograde extracorporeal flow was unlikely to be favourable with respect to progression of the dissection and planned weaning. Flow was reduced to 500 mL/min, the circuit removed, cardiac contraction deteriorated within minutes, and cannulation was re-established. By 00:26 flow had fallen to 0.53 - 0.55 L/min; pulseless electrical activity occurred at 01:06 and death was declared at 01:51 on the following calendar day. Malperfusion was diagnosed and treated; the patient died of coagulopathic haemorrhage and refractory circulatory failure.

3. Discussion

3.1. Pressure Topography as a Branch-Vessel Map

Two arterial sites—the left radial and right femoral arteries—were monitored from induction. A third, in the right upper limb, was placed at 15:36, after the first two had failed; the three sites were therefore not monitored simultaneously throughout, and the comparison that first raised concern was between two sites only. The two original catheters remained in situ but produced no waveform from 15:10, and the record does not state whether they remained connected to the monitor after the new line was placed.

Taken together, the sites produced a spatial pattern that matched the branch-vessel involvement later shown on computed tomography (Table 1). That correspondence was available at the bedside about an hour before the imaging diagnosis and required no additional equipment. Where more than one arterial site is monitored, discordance between sites is itself a finding, and in this patient, it was informative when mapped anatomically rather than averaged or dismissed. A preserved site did not exclude malperfusion here; it indicated which territory was preserved.

3.2. Why the Distal Site Failed First

It is worth separating what imaging established from what remains conjecture. Computed tomographic angiography established the anatomy: dissection extending to both external iliac arteries, dynamic obstruction of the right iliac and left

Table 1. Correspondence between arterial monitoring sites and branch-vessel anatomy.

Monitored site	Supplying branch	Finding on computed tomographic angiography	Arterial pressure
Left radial artery (from induction)	Left subclavian artery	Involved in the dissection	No waveform from 15:15
Right femoral artery (from induction)	Right iliac artery	Dynamic obstruction	Fell to 17 - 20 mmHg at 14:50; no waveform from 15:10
Right upper limb (placed 15:36)	Innominate artery	Not described in the report	Normal
Not monitored	Left renal artery	Dynamic obstruction	Urine output fell from 1570 to 170 mL
Not monitored	Superior mesenteric, right renal and inferior mesenteric arteries	Arising from the true lumen	-

Both territories that failed were shown to be involved or dynamically obstructed. The preserved site was supplied by the innominate artery, which the computed tomography report did not describe. Monitoring was not simultaneous at all three sites: the left radial and right femoral lines were in place from induction, and the right upper-limb line was placed at 15:36.

renal arteries, and involvement of the left common carotid and left subclavian arteries. The observed sequence—right femoral before left radial—was therefore distal before proximal, and each failing site corresponded to a vessel reported as obstructed or involved. Those are the findings.

The mechanism is not established. Williams and colleagues distinguished dynamic obstruction, in which the dissection spares the vessel origin but the flap compresses the true lumen at or above the origin and covers it, from static obstruction, in which the dissection narrows the ostium itself [5]; in acute type A dissection, dynamic obstruction is the more common mechanism, reported to account for approximately 80% of malperfusion [6]. Progressive false lumen pressurisation with dynamic true lumen compression, aggravated by haemorrhage reducing the distending pressure within the true lumen, is consistent with both the imaging and the chronology, including the later failure of the left subclavian territory. This remains an inference from the imaging and the sequence of events; serial imaging that would have demonstrated progressive true lumen compression was not obtained.

Two further possibilities deserve mention and neither can be resolved here. First, the geometry of retrograde femoral return may have contributed: with the cannula in the left femoral artery and native ejection minimal, the right iliac territory had lost its antegrade source and depended on flow redistributing across the aortic bifurcation. This is a hypothesis only, and it does not by itself account for the later loss of the left subclavian territory. Second, because the dissection extended to both external iliac arteries, the cannula may have lain within a dissected segment, and false lumen perfusion by the cannula could have contributed to true lumen compression. The images available to us did not allow the position of the cannula tip relative to the true and false lumens to be determined.

3.3. Which Numbers Misled, and Which Did Not

At 14:50, the decision to transfer rested on two variables: circuit flow, unchanged at 4.0 L/min, and a left radial pressure of 72/66 mmHg. Both were reassuring, and neither could report what a dissected aorta was doing with the blood the circuit delivered. In this patient, the contralateral femoral line was the first site to change and also the site whose reading was most readily attributed to artefact; the change was not acted upon as a vascular finding. Whether such a line is generally the earliest indicator of branch malperfusion during retrograde femoral support cannot be determined from a single case.

The interval between the first discrepancy at 14:50 and the transoesophageal study at 15:46 is itself instructive, and it was not a period of inaction. The discordance arose during transfer, at the moment the patient was moved between beds and from the operating room monitor to the intensive care unit monitor—the point in a patient's course at which loss of a trace is most naturally attributed to the equipment. Replacement monitoring equipment was requested and brought, and only when the substituted system also produced no waveform at either site did attention turn from the monitoring chain to the patient; obtaining the echocardiography machine then took further time. The sequence illustrates a practical difficulty: discordance between arterial sites is most likely to appear when a patient is being moved and least likely to be read anatomically at that moment.

By 15:30, the metabolic data had declared themselves—lactate 7.0 mmol/L and base excess −9.3 mmol/L—while the arterial pH was normal at 7.390 because the pCO_2 had fallen to 23.2 mmHg, with saturation 99.9% and PaO_2/FiO_2 684. Of the variables available at that moment, pH, saturation and oxygenation were all reassuring and all misleading; lactate and base excess were not, and the team acted on them, performing TEE 16 minutes later. The base excess then fell monotonically—−9.3 at 15:30, −13.0 at 17:16, −19.2 at 19:55 and −23.1 at 20:44—whereas the pH stayed near the reference range until 17:16. Sweep gas flow is operator-set and clears carbon dioxide independently of the patient's own ventilation, which offers a plausible explanation for an apparently normal pH persisting past the point at which metabolic deterioration was established. In this patient, a normal arterial pH was not reassuring, and base excess, bicarbonate and lactate were the informative variables.

3.4. What Transoesophageal Echocardiography Could and Could Not Answer

TEE identified the flap, which was the finding that mattered. It could not have established the extent of the dissection: the abdominal aorta and iliac vessels are not accessible to transoesophageal imaging, and impaired visualisation of the distal ascending aorta and arch, attributed to the air-filled trachea, is a recognised blind spot [7]. The lesson is not that the examination should have been more extensive, but that when pressure discordance involves a sub-diaphragmatic site,

TEE cannot answer the question being asked and computed tomographic angiography is required. Here the interval from flap detection to imaging was 47 minutes.

3.5. Competing Imperatives: Malperfusion and Haemorrhage

Once the dissection was defined, three requirements were mutually incompatible. Support required anticoagulation. Dynamic obstruction of the left renal and right iliac arteries, with absent lower limb pulses and a documented concern for spinal cord ischaemia, required an intervention directed at restoring end-organ flow [6], which occupied 95 minutes. Bleeding—1300 mL of chest drainage by 15:55, with bilateral haemothorax—required haemostasis.

Haemorrhage was documented about two hours before reperfusion began, and it determined the outcome. Re-exploration, however, found no active bleeding site. We cannot say what an earlier examination would have found: the absence of a focal source at 20:45 does not establish that none existed earlier, and the finding at that time was of diffuse oozing rather than a controllable vessel. The coagulation studies place the onset of the coagulopathy earlier than the major haemorrhage. At 15:27, before the transoesophageal study that first showed the flap and some two and a half hours before fenestration, the fibrinogen was already 72 mg/dL and the prothrombin time 36.9 s, against a normal study on admission. The conflict was therefore not created by the decision to reperfuse: a consumptive coagulopathy was established before the dissection had been diagnosed. What the course illustrates is that coagulopathy and malperfusion ran in parallel in a patient who could not be supported without an anticoagulated circuit—a conflict that better sequencing alone may not have resolved. Consumptive coagulopathy is characteristic of early venoarterial support: compared with venovenous patients, those on venoarterial support have lower platelet counts, fibrinogen and antithrombin with higher d-dimer, and bleeding occurs at a median of 0.3 days from initiation [8]. We note that the pleural spaces were not opened at the index operation, yet computed tomography showed bilateral haemothorax, suggesting that part of the intrathoracic blood arose from the dissected aorta rather than the surgical field, although this was not confirmed.

3.6. Aetiology

The origin cannot be established and the primary tear was not localised radiologically. What follows is a set of candidate explanations, none of which was confirmed by intraoperative inspection or by imaging. Iatrogenic dissection in this setting is most often attributed to aortic cannulation, cross-clamping or aortotomy [1]. Preoperative imaging showed no dissection and TEE before and immediately after bypass showed no flap; separation was uneventful and collapse began only after chest closure, so a quiet interval separated aortic instrumentation from haemodynamic deterioration—a sequence consistent with, but not proof of, a tear present and initially without haemodynamic consequence. Every instrumented site lay on

the ascending aorta or root. The surgeon reported that the straight-tip cannula was advanced deeper than his customary position, and a straight-tip cannula seated more distally would direct its jet further along the arch; the dissection involved the left common carotid and left subclavian arteries, the territory such a jet would encounter. That correspondence is suggestive and no more: the cannula position was reported verbally and was not recorded in the operative note, and no entry tear was identified at that site or elsewhere. The aortotomy was also reinforced with a pericardial patch and sealed with glue, indicating that the surgeon did not regard the aortic wall as robust.

Extracorporeal support may have acted as an amplifier rather than a cause: the first malperfusion event followed the start of retrograde flow by ten minutes at unchanged circuit flow. This does not show that support created the dissection, and the temporal association is equally compatible with a dissection that was already progressing. As substrate, the patient was 73 with hypertension, diabetes and a 40.3 mm ascending aorta. The valve was tricuspid, so bicuspid aortopathy does not apply, and we do not attribute causation to the valve lesion itself.

3.7. Possible Substrates for the Rhythm Disturbance

Two explanations are available and neither can be confirmed. The atrioventricular conduction axis runs beneath the membranous septum and, after entering the subaortic outflow tract, usually gives off the right bundle branch at the level of the interleaflet fibrous triangle between the non-coronary and right coronary aortic sinuses [9]. Deep annular debridement in the region of the non-coronary cusp, as the surgeon described, would place instrumentation close to that axis and offers a coherent explanation for a postoperative rhythm disturbance of junctional character in a patient whose preoperative rhythm was sinus. Against this, no tracings were retained and the extent of decalcification was described verbally, so the association cannot be examined.

Myocardial ischaemia from involvement of the aortic root or a coronary ostium is an equally plausible alternative, particularly for the ventricular tachycardia. The computed tomographic report did not describe the aortic root or the coronary ostia, and no coronary imaging or troponin trend from this interval is available to us, so root or ostial involvement can be neither demonstrated nor excluded. The concurrent fall in the PaO_2/FiO_2 ratio and the vasopressor requirement are consistent with either explanation.

3.8. Limitations

This is a single retrospective report and its observations are hypothesis-generating. It cannot establish the sensitivity or specificity of arterial pressure discordance for aortic dissection, nor demonstrate that any intervention altered survival. Arrhythmia, hypoxaemia and vasopressor-dependent shock all preceded the pressure changes: the discordance was the first finding pointing to a vascular cause, not the first abnormality of any kind. The three sites were not monitored simul-

taneously throughout—two from induction, the third from 15:36. Both lines were re-tested on substituted monitoring equipment and neither produced a waveform, and the non-invasive pressure and carotid pulsation were concordant with the surviving site, so monitoring failure is unlikely to account for the findings; that sequence is, however, reported by the attending team and only partly documented, and the record does not itemise the checks performed on the individual lines and transducers.

The proposed mechanisms of distal-before-proximal malperfusion are inferred from imaging and chronology and were not demonstrated. The primary tear was not localised; the report did not describe the innominate artery, the aortic root or the coronary ostia; and the available images did not allow the position of the femoral cannula tip relative to the true and false lumens to be determined. Re-exploration was directed at haemostasis rather than inspection of the aorta, so no macroscopic description of the dissected aorta is available. Two details central to the aetiological discussion—the depth of cannula placement and the extent of decalcification toward the non-coronary cusp—were reported verbally by the operating surgeon and are not in the operative note. No rhythm tracings were retained. The platelet count was not retrievable, so disseminated intravascular coagulation is reported as the attribution recorded by the clinical team, supported by the prothrombin time, the fibrinogen and the fibrin markers but without a formal score; heparin dosing was likewise not recorded in a retrievable form. Extracorporeal flow was not varied in a documented manner before re-exploration. Point-of-care blood gas results reached the electronic record only in part; transfusion volumes were not quantified. Laboratory times are those of specimen receipt.

4. Conclusion

In a patient supported by retrograde femoral VA-ECMO after aortic valve replacement, the first finding that pointed to a vascular cause of deterioration was discordance between arterial pressure sites, at a time when circuit flow was unchanged and the upper-limb arterial pressure was normal. The spatial pattern of that discordance corresponded to the branch-vessel anatomy later shown on computed tomography, and the metabolic deficit that followed was visible in base excess and lactate while the arterial pH remained normal. A single case cannot establish how often this pattern occurs or how reliably it identifies dissection. The observation we would offer is a practical one: where more than one arterial site is monitored during extracorporeal support, discordance between them may carry anatomical information and is worth interpreting as such before it is attributed to a monitoring fault.

Ethics Approval

This case report was reviewed by the Institutional Review Board of Ajou University Hospital, which determined on 22 October 2026 that it was exempt from formal review (approval No. AJOUIRB-EX-2026-622).

Informed Consent

The patient died during the index admission, and written informed consent could not be obtained from him. The Institutional Review Board of Ajou University Hospital waived the requirement for informed consent, having determined that consent could not practicably be obtained, that there was no reason to suppose the patient would have refused participation, and that the waiver posed a minimal risk to the safety, rights and welfare of the subject. The protocol reviewed by the board specified publication of the de-identified case in a peer-reviewed journal. All potentially identifying information has been removed; no identifiable images or data are presented, and no calendar dates are reported.

Conflicts of Interest

The authors declare no conflicts of interest regarding the publication of this paper.

References

[1] Leontyev, S., Borger, M.A., Legare, J.F., Merk, D., Hahn, J., Seeburger, J., *et al.* (2012) Iatrogenic Type A Aortic Dissection during Cardiac Procedures: Early and Late Outcome in 48 Patients. *European Journal of Cardio-Thoracic Surgery*, **41**, 641-646. https://doi.org/10.1093/ejcts/ezr070

[2] Czerny, M., Schoenhoff, F., Etz, C., Englberger, L., Khaladj, N., Zierer, A., *et al.* (2015) The Impact of Pre-Operative Malperfusion on Outcome in Acute Type A Aortic Dissection: Results from the GERAADA Registry. *Journal of the American College of Cardiology*, **65**, 2628-2635. https://doi.org/10.1016/j.jacc.2015.04.030

[3] Banfi, C., Pozzi, M., Brunner, M., Rigamonti, F., Murith, N., Mugnai, D., *et al.* (2016) Veno-Arterial Extracorporeal Membrane Oxygenation: An Overview of Different Cannulation Techniques. *Journal of Thoracic Disease*, **8**, E875-E885. https://doi.org/10.21037/jtd.2016.09.25

[4] Gagnier, J.J., Kienle, G., Altman, D.G., Moher, D., Sox, H. and Riley, D. (2013) The CARE Guidelines: Consensus-Based Clinical Case Reporting Guideline Development. *Global Advances in Health and Medicine*, **2**, 38-43. https://doi.org/10.7453/gahmj.2013.008

[5] Williams, D.M., Lee, D.Y., Hamilton, B.H., Marx, M.V., Narasimham, D.L., Kazanjian, S.N., *et al.* (1997) The Dissected Aorta: Part III. Anatomy and Radiologic Diagnosis of Branch-Vessel Compromise. *Radiology*, **203**, 37-44. https://doi.org/10.1148/radiology.203.1.9122414

[6] Lou, X. and Chen, E.P. (2022) Malperfusion Syndromes in Acute Type A Aortic Dissection. *Vessel Plus*, **6**, Article 38. https://doi.org/10.20517/2574-1209.2021.108

[7] Jansen Klomp, W.W., Peelen, L.M., Brandon Bravo Bruinsma, G.J., van't Hof, A.W.J., Grandjean, J.G. and Nierich, A.P. (2015) Modified Transesophageal Echocardiography of the Dissected Thoracic Aorta; a Novel Diagnostic Approach. *Cardiovascular Ultrasound*, **14**, Article No. 28. https://doi.org/10.1186/s12947-016-0071-6

[8] Cartwright, B., Bruce, H.M., Kershaw, G., Cai, N., Othman, J., Gattas, D., *et al.* (2021) Hemostasis, Coagulation and Thrombin in Venoarterial and Venovenous Extracorporeal Membrane Oxygenation: The HECTIC Study. *Scientific Reports*, **11**, Article No. 7975. https://doi.org/10.1038/s41598-021-87026-z

[9] Cabrera, J.-Á, Anderson, R.H., Porta-Sánchez, A., Macías, Y., Cano, Ó., Spicer, D.E.,

et al. (2021) The Atrioventricular Conduction Axis and Its Implications for Permanent Pacing. *Arrhythmia & Electrophysiology Review*, **10**, 181-189. https://doi.org/10.15420/aer.2021.32