Open Access Library Journal
2026, Volume 13, e15828
ISSN Online: 2333-9721
ISSN Print: 2333-9705

Surgical Management of Excessive Gingival Display by LipStaT Technique: A Case Report

Rayhana Malek[1*], Ansam Lahrizia[2], Amina Gharibi[2], Asmaa El Mabrak[3], Jamila Kissa[2]

[1]Department of Biology and Fundamentals, Faculty of Dental Medicine, Hassan II University of Casablanca, Casablanca, Morocco
[2]Department of Periodontology, Faculty of Dental Medicine, Hassan II University of Casablanca, Casablanca, Morocco
[3]Department of Orthodontics, Faculty of Dental Medicine, Hassan II University of Casablanca, Casablanca, Morocco
Email: *rayhana.malek@gmail.com, Alahrizia@outlook.com, gharibiamina@gmail.com, asmaa.elmabrak@gmail.com, jamilakissa@yahoo.fr

How to cite this paper: Malek, R., Lahrizia, A., Gharibi, A., El Mabrak, A. and Kissa, J. (2026) Surgical Management of Excessive Gingival Display by LipStaT technique: A Case Report. *Open Access Library Journal*, **13**: e15828.
https://doi.org/10.4236/oalib.1115828

Received: July 30, 2026
Accepted: November 22, 2026
Published: November 25, 2026

Copyright © 2026 by author(s) and Open Access Library Inc.
This work is licensed under the Creative Commons Attribution International License (CC BY 4.0).
http://creativecommons.org/licenses/by/4.0/
Open Access

Abstract

Background: Excessive gingival display, referred to "gummy smile", is a frequent aesthetic concern affecting approximately 10% of young adults, with a higher prevalence in females. Many factors can lead to excessive gingival display, the most involved is a hypermobile or a short upper lip. The Lip repositioning surgery has emerged as a minimally invasive and predictable treatment approach. **Case Presentation:** A 40-year-old female patient presenting with 4 - 6 mm of gingival display underwent lip repositioning surgery. The "LipstaT" technique was chosen, it involved a canine-to-canine mucosal strip excision based on a 2:1 ratio, with suturing initiated at the midline and progressing bilaterally. Complete gummy smile resolution was achieved at 8 weeks, and almost maintained at the 12-month follow-up. After that, Minimal relapse was observed. The patient reported high aesthetic satisfaction throughout follow-up. Lip repositioning surgery with LipStaT technique is effective, safe, and delivers durable aesthetic outcomes with minimal morbidity.

Subject Areas

Dentistry

Keywords

Gummy Smile, Excessive Gingival Display, Lip Repositioning Surgery, Periodontal Surgery, Lipstat Technique, Aesthetic Dentistry

1. Introduction

Excessive gingival display EGD, commonly referred to "gummy smile", is defined as the exposure of more than 2 - 3 mm of gingival tissue during maximum smile

making a unattractive smile filing [1]. Indeed, a Brazilian study assessed oral health-related quality of life between individuals with and without EGD. It was observed that the aesthetic satisfaction of patients with EGD was 21.1%, while for control patients it was 78.9% [2].

The prevalence of EGD is estimated at approximately 10% among individuals aged 20 - 30 years, with a significantly higher prevalence in females [3]. A study highlighted previously that EGD affects 14% of females and 7% of males [4]. The etiology of EGD is multifactorial and may involve dento-alveolar factors such as short clinical crowns, extrusion, gingival hypertrophy and altered passive eruption, the non dento-alveolar factors involve vertical maxillary excess and hyperactive labial muscles, short or incompetent lip [3] [5] [6].

The management of EGD depends on the underlying etiology. It may include orthognathic surgery, orthodontic intrusion, crown lengthening, botulinum toxin injection, or lip repositioning surgery [7]-[10]. Among these options, lip repositioning surgery stands out as a minimally invasive, and cost-effective approach, this approach is indicated when hypermobility of the upper lip is a main factor [8] [10].

First described by Rubinstein and Kostianovsky in 1973, Lip Repositioning Surgery (LRS) aimed to restrict the upward movement of the upper lip by shortening the depth of vestibular sulcus. So that, it limits the retraction of the elevators of the upper lip muscles, thereby reducing gingival exposure during smile [11]. Bhola *et al.* in 2015 have modified this surgical technique by excising vestibular mucosal tissue about twice the amount of gingival exposure during maximal smile [6]. Various modifications of the original technique have been proposed as: adding a myotomy of the lip elevator muscles [12], an internal periosteal suture in order to reduce the risk of relapse [9] [10] [13] also maintaining labial frenum [2] [8] [14] was recommended as modification to keep midline reference for symmetry, reduce post-operative morbidity then optimize outcomes.

The present case report describes the surgical management of EGD with lip repositioning surgery LipStaT, and highlights clinical outcomes at 12 months follow up.

2. Case Presentation

A 40-year-old systemically healthy female patient was referred to the Department of Periodontology of the University of Hassan II of Casablanca-Morocco with a chief complaint of excessive gingival display EGD. A meticulous clinical examination (in concertation with Dr. A. EL. M.) was performed to rule out any skeletal or dento-gingival related factors. Dynamic smile assessment revealed 4 - 6 mm of gingival exposure on maximum smile caused by a hypermobile upper lip (measured with millimeter ruler by Dr. R.M). Otherwise Periodontal status was stable, with no signs of active periodontal disease (**Figure 1**). So that, after a pointed diagnosis, a lip repositioning surgery by LipStaT technique was advocated.



Figure 1. Full smile at baseline exhibiting 4 - 6 mm of gummy smile.

Following local anesthesia (articaine with 1:100.000 adrenaline) infiltrated in vestibular sulcus, two parallel horizontal incisions were designed from canine-to-canine, following the dynamic smile width established during pre-surgical assessment. The inferior incision was placed at the mucogingival junction, while the superior incision was marked 9 - 10 mm apically in the labial mucosa, based on a 2:1 ratio as described by Bhola *et al.* in the LipStaT technique, approximately twice the measured gingival exposure at full dynamic smile [6]. Vertical releasing incisions were placed bilaterally to connect the two horizontal lines, creating a rectangular mucosal outline. A split-thickness dissection was performed to excise the full mucosal strip, exposing the underlying connective tissue. A concomitant labial frenectomy was subsequently carried out to eliminate the midline frenum attachment (**Figure 2**).

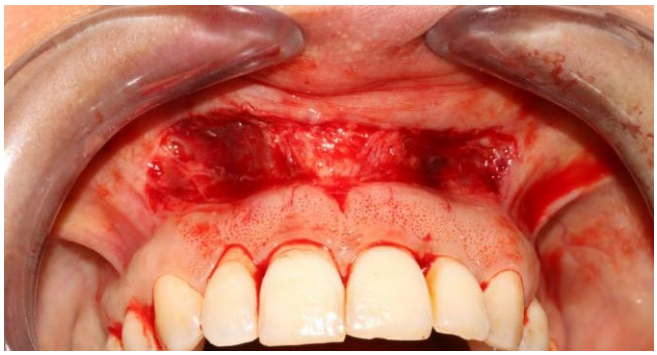

Figure 2. Mucosal strip excision exposing the underlying connective tissue.

A midline reference anchored suture was placed to preserve mesiodistal lip orientation. interrupted sutures were then performed to stabilize mucosal margins the keratinized gingiva using 4-0 polyglycolic acid sutures. The sutures started at the midline and progressed bilaterally from mesial to distal, ensuring optimal tissue alignment and bilateral symmetry (**Figure 3**).



Figure 3. Interrupted sutures stabilizing the repositioned mucosal margin to the keratinized gingiva.

Postoperative instructions included local ice application for the first 24 hours. Systemic medication consisted of amoxicillin 1 g twice daily for 7 days, paracetamol 1 g three times daily for 3 days, and prednisolone 60mg daily for 3 days. The patient was instructed to: restrict active lip movement, avoid mechanical plaque control during the initial healing phase, and to use 0.12% chlorhexidine mouthwash twice daily for 2 weeks. Sutures were removed after 15 days; gentle tooth brushing was resumed with soft toothbrush.

Immediate postoperative examination confirmed adequate surgical site stability and satisfactory lip positioning with no signs of dehiscence or asymmetry. The patient was quite satisfied with the results of the treatment (**Figure 4**).



Figure 4. Immediate postoperative view showing lip repositioning.

At the 8-week follow-up, complete resolution of the gummy smile was achieved. The healing was uneventful, without any complications (**Figure 5**).

At the 12-month follow-up, a stable 3 - 4 mm net reduction in gingival display from baseline was maintained (especially at the incisors). But a minimal relapse inferior to 2mm was noted (all assessments at each time were done with the same device and by the same operator Dr. R.M.). The patient expressed high aesthetic satisfaction throughout the follow-up period (**Figure 6**).



Figure 5. 8-week postoperative result demonstrating complete reduction of the gummy smile.



Figure 6. 12-month follow-up revealing a good aesthetic improvement.

3. Discussion

The present case report shows a successful surgical management of EGD with LipStat technique described by Bhola *et al.* [6]. Indeed, the amount of mucosa resected was determined according to the 2:1 ratio as described in the surgical technique, for an initial display of 4 - 6 mm, this yielded an excision of 9 - 10 mm. This ratio has been shown to provide predictable correction while preserving sufficient tissue for tensionless closure [6] comparing to Rubinstein and Kostianovsky technique in which no measurements were expected [11].

Midline Frenum preservation was recommended in lip repositioning surgery LRS in order to maintain reference for lip symmetry and reduce post-operative morbidity [7] [9] [14]. However, maintaining the frenum attached could lead to lip tension at the midline area and non-harmonious smile [8]. So that, a "knot reference" might be placed in the frenum prior its excision as proposed by El kholti *et al.* [8]. In the present case report, the frenectomy was incorporated in the surgery as described in the LipStaT technique. Postoperative controls showed a perfect symmetry respecting over time.

Many authors performed myotomy of the lip elevator muscles additionally to the LRS to avoid recurrence of EGD [11] [15]-[17]. Indeed, Tawfik *et al.* demonstrated that the addition of myotomy to LRS increased the mean reduction in gingival display of 2.73 mm (without myotomy) to 3.57 mm (with myotomy), with greater stability at 12 months [18]. Also, Alammar *et al* showed in 2 prospective studies satisfactory and stable clinical outcomes of the LRS with myotomy comparing to LRS without myotomy after 6 months [16] and 12 months of follow-up [17]. However, the myotomy could be considered as an aggressive procedure with doubtful outcomes and high post-operative morbidity [8]. Alammar *et al.* reported some temporary complications such as Numbness and flap dehiscence in 64.2% and 14.2% of cases respectively [16].

A novel approach was assessed recently consisting of LRS with adjunctive internal dual muscle traction of the labial muscles (iMTA) [9]. The authors compared 10 patients treated with LRS alone and 10 others treated with iMTA approach. On comparing EGD in both groups, the gummy smile reduction achieved by iMTA group was superior to the control group (2.7 mm versus 1.6 mm respectively) at 12-month follow-up. Besides, satisfaction scores were significantly reported in the iMTA group when compared to the control one (9.3 versus 7.8). The LRS with internal dual muscular traction approach could be an effective procedure for reducing EGD caused by upper lip elevator muscle hypermobility [9].

In the present case report, neither myotomy nor muscle traction was performed, given the satisfactory result achieved, these additional steps were deemed unnecessary.

Suturing is mandatory step in LRS, in this case report, sutures started at the midline and extended bilaterally from mesial to distal equitably in each side as described in LipStaT technique [6]. This approach ensures early midline stabilization and allows progressive bilateral adaptation of the tissue margins. This contrasts with the original Rubinstein and Kostianovsky technique, in which suturing proceeds linearly from one side to the other, without midline prioritization [11]. The midline-first approach theoretically reduces the risk of asymmetry and may contribute to more predictable aesthetic outcomes.

Adding a specific suture was defended by many reports [9] [10] [13] [19]-[21]. A prospective study in a population of 12 twins with EGD, showed higher satisfaction and more stable results in group treated with lip repositioning technique that utilized periosteal sutures comparing to the classical technique over a 3.5-year follow-up [10].

Another study analyzed 4 patients with 6 to 8 mm of excessive gingival display (EGD) whom underwent Modified LipStaT sugery with internal horizontal mattress sutures to immobilize labial muscles. All patients demonstrated stability over a 3.5-year follow-up period [19].

Recently, A randomized clinical trial with 200 patients confirmed the greater stability without reccurence of EGD with the modified LRS with the addition periosteal sutures versus the conventional LRS, up to one year of follow-up [21].

Relapse is the main disadvantage following LRS. A systematic review reported a relapse rate of 25% at 6-month Follow up [22]. This phenomenon is attributed to incomplete scar maturation, residual muscular overactivity, or premature resumption of unrestricted lip movement during the early healing phase [15]. Periosteal sutures have been proposed as a strategy to anchor the repositioned lip more rigidly and minimize relapse [13].

In the present case report, the reduction of gingival exposure was of 4 mm at 8-week follow-up, it is consistent with the finding of a systematic review of Tawfik *et al.*, in which the reduction in gingival exposure observed following a LipStat technique was of 3.4 mm [22]. However, A minimal relapse of less than 2mm was noted in the present case between the 8-week and 12-month assessments. This recurrence might be explained by the conventional sutures done instead of the periosteal sutures. Despite the modest relapse observed, the patient maintained high aesthetic satisfaction, confirming that a clinically meaningful and durable improvement was achieved.

4. Conclusion

Lip repositioning surgery by LipStat technique is an effective, minimally invasive, and reproducible treatment for the management of excessive gingival display. The suturing sequence is as mandatory as the whole surgery, it enables precise lip repositioning with good bilateral symmetry. At 12-month follow-up, stable aesthetic improvement was achieved with minimal relapse and no significant complications. This technique represents a valuable option in the periodontal-aesthetic surgical armamentarium, and further prospective studies with larger sample sizes and longer follow-up periods are needed to establish standardized protocols and optimize long-term stability.

Author Contributions

Pr. MALEK Rayhana: Treatment procedures (surgery and follow-up), Literature review, manuscript preparation; Dr. LAHRIZIA Ansam: Literature review, manuscript preparation; Pr. GHARIBI Amina: Editing and review; Pr. EL MABRAK Asmaa: Treatment procedures (orthodontic consultation and handling). Pr. KISSA Jamila: Editing and review.

Conflicts of Interest

The authors declare that they have no conflicts of interest.

References

[1] Garber, D.A. and Salama, M.A. (1996) The Aesthetic Smile: Diagnosis and Treatment. *Periodontology* 2000, **11**, 18-28. https://doi.org/10.1111/j.1600-0757.1996.tb00179.x

[2] Antoniazzi, R.P., Fischer, L.d.S., Balbinot, C.E.A., Antoniazzi, S.P. and Skupien, J.A. (2017) Impact of Excessive Gingival Display on Oral Health-Related Quality of Life

in a Southern Brazilian Young Population. *Journal of Clinical Periodontology*, **44**, 996-1002. https://doi.org/10.1111/jcpe.12753

[3] Tjan, A.H.L., Miller, G.D. and The, J.G.P. (1984) Some Esthetic Factors in a Smile. *The Journal of Prosthetic Dentistry*, **51**, 24-28. https://doi.org/10.1016/s0022-3913(84)80097-9

[4] Geron, S. and Atalia, W. (2005) Influence of Sex on the Perception of Oral and Smile Esthetics with Different Gingival Display and Incisal Plane Inclination. *The Angle Orthodontist*, **75**, 778-784.

[5] Robbins, J.W. (1999) Differential Diagnosis and Treatment of Excess Gingival Display. *Practical Periodontics and Aesthetic Dentistry*, **11**, 265-272.

[6] Bhola, M., Fairbairn, P.J., Kolhatkar, S., Chu, S.J., Morris, T. and de Campos, M. (2015) LipStaT: The Lip Stabilization Technique—Indications and Guidelines for Case Selection and Classification of Excessive Gingival Display. *The International Journal of Periodontics & Restorative Dentistry*, **35**, 549-559. https://doi.org/10.11607/prd.2059

[7] Arruda, C.A.S., Sousa, F.P. and Alves, R.C. (2024) Modified Lip Repositioning Surgery in the Treatment of Gummy Smile. *Applied Sciences* (*Basel*), **14**, Article No. 5580. https://doi.org/10.3390/app14135580

[8] El Kholti, W., Amine, K. and Kissa, J. (2023) Surgical Management of Excessive Gingival Display by a Modified Lip Repositioning Technique. *Odonto-Stomatologie Tropicale*, **46**, 5-11.

[9] Hazzaa, H.H., Elwakeel, N.M., Abdulhady, E.M. and Abdel-Aziz, L.M. (2022) Evaluation of the Internal Dual Muscle Traction Approach as an Adjunct to the Modified Surgical Lip Repositioning Method: A Randomized Clinical Report. *Journal of Oral and Maxillofacial Surgery, Medicine, and Pathology*, **34**, 12-18. https://doi.org/10.1016/j.ajoms.2021.05.002

[10] Al Jasser, R.N., Al Sarhan, M.A., Alotaibi, D.H. and Bhola, M. (2021) A Modified Approach in Lip Repositioning Surgery: A Prospective Study in a Twin Population with a 3-Year Follow-Up. *The International Journal of Periodontics & Restorative Dentistry*, **41**, e243-e253. https://doi.org/10.11607/prd.4707

[11] Rubinstein, A.M. and Kostianovsky, A.S. (1973) Cosmetic Surgery for the Malformation of the Laugh: Original Technique. *La Prensa Médica Argentina*, **60**, 952.

[12] Ishida, L.H., Ishida, L.C., Ishida, J., Grynglas, J., Alonso, N. and Ferreira, M.C. (2010) Myotomy of the Levator Labii Superioris Muscle and Lip Repositioning: A Combined Approach for the Correction of Gummy Smile. *Plastic and Reconstructive Surgery*, **126**, 1014-1019. https://doi.org/10.1097/prs.0b013e3181e3b6d4

[13] Al Jasser, R.N., Alsharif, M.H. and Andreana, S. (2019) Lip Repositioning Surgery with Periosteal Sutures for Treatment of Excessive Gingival Display: A Case Report and Review of the Literature. *Clinical Advances in Periodontics*, **9**, 68-74.

[14] Silva, C.O., Ribeiro-Júnior, N.V., Campos, T.V.S., Rodrigues, J.G. and Tatakis, D.N. (2013) Excessive Gingival Display: Treatment by a Modified Lip Repositioning Technique. *Journal of Clinical Periodontology*, **40**, 260-265. https://doi.org/10.1111/jcpe.12046

[15] Rosenblatt, A. and Simon, Z. (2006) Lip Repositioning for Reduction of Excessive Gingival Display: A Clinical Report. *International Journal of Periodontics & Restorative Dentistry*, **26**, 433-437.

[16] Alammar, A.M. and Heshmeh, O.A. (2018) Lip Repositioning with a Myotomy of the Elevator Muscles for the Management of a Gummy Smile. *Dental and Medical Prob-*

lems, **55**, 241-246. https://doi.org/10.17219/dmp/92317

[17] Alammar, A., Heshmeh, O., Mounajjed, R., Goodson, M. and Hamadah, O. (2018) A Comparison between Modified and Conventional Surgical Techniques for Surgical Lip Repositioning in the Management of the Gummy Smile. *Journal of Esthetic and Restorative Dentistry*, **30**, 523-531. https://doi.org/10.1111/jerd.12433

[18] Tawfik, O.K., Naiem, S.N., Tawfik, L.K., Yussif, N., Meghil, M.M., Cutler, C.W., *et al.* (2018) Lip Repositioning with or without Myotomy: A Randomized Clinical Trial. *Journal of Periodontology*, **89**, 815-823. https://doi.org/10.1002/jper.17-0598

[19] Mateo, E., Collins, J., Rivera, H. and Nart, J. (2021) New Surgical Approach for Labial Stabilization: A Long-Term Follow-Up Case Series. *The International Journal of Periodontics & Restorative Dentistry*, **41**, 405-410. https://doi.org/10.11607/prd.4668

[20] Adel, N. (2024) Modified Lip Repositioning Surgery with and without Dual-Layered Suturing for Treatment of Gummy Smile Patients. *Plastic and Reconstructive Surgery—Global Open*, **12**, e5521. https://doi.org/10.1097/gox.0000000000005521

[21] AlJasser, R.N. (2023) A Modified Approach in Lip Repositioning Surgery for Excessive Gingival Display to Minimize Post-Surgical Relapse: A Randomized Controlled Clinical Trial. *Diagnostics*, **13**, Article No. 716. https://doi.org/10.3390/diagnostics13040716

[22] Tawfik, O.K., El-Nahass, H.E., Shipman, P., Looney, S.W., Cutler, C.W. and Brunner, M. (2018) Lip Repositioning for the Treatment of Excess Gingival Display: A Systematic Review. *Journal of Esthetic and Restorative Dentistry*, **30**, 101-112. https://doi.org/10.1111/jerd.12352