Case Reports in Clinical Medicine, 2026, 15(11), 507-515
https://www.scirp.org/journal/crcm
ISSN Online: 2325-7083
ISSN Print: 2325-7075

Preauricular Dermoid Cyst with a Cartilaginous Component in a Child: A Case Report and Diagnostic Considerations

Abdullah Saleh Alkhamiss[1,2], Faisal Abdulaziz Alhamed[1], Aseel Saleh Alnugaithan[1], Hasan Homood Alsughayer[2], Khaled Ali Aleridi[2], Yunes Abdulaziz Alothaim[3], Abdulrahman Abdulmuhsen Alsultan[3], Nasser Ali Alhussain[4], Mohammed Ali Alkhamis[5], Ahmed Mohammed Alsolai[1,2], Ali Yousif Babiker[1,6*]

[1]Department of Laboratory and Blood Bank, Medical Laboratory, Qassim University Medical City, Qassim University, Buraidah, Saudi Arabia
[2]Department of Pathology, College of Medicine, Qassim University, Buraidah, Saudi Arabia
[3]Department of Anatomy and Histology, College of Medicine, Qassim University, Buraidah, Saudi Arabia
[4]Department of Compliance Management, Inspection, and Control, Qassim Health Affairs General Directorate, Ministry of Health, Buraidah, Saudi Arabia
[5]Department of Nursery, Alrass General Hospital, Qassim Health Complex, Buraidah, Saudi Arabia
[6]Department of Histopathology & Cytology, College of Medical Laboratory Sciences, University of Garden City, Khartoum, Sudan
Email: *alibabkr99@gmail.com

How to cite this paper: Alkhamiss, A.S., Alhamed, F.A., Alnugaithan, A.S., Alsughayer, H.H., Aleridi, K.A., Alothaim, Y.A., Alsultan, A.A., Alhussain, N.A., Alkhamis, M.A., Alsolai, A.M. and Babiker, A.Y. (2026) Preauricular Dermoid Cyst with a Cartilaginous Component in a Child: A Case Report and Diagnostic Considerations. *Case Reports in Clinical Medicine*, **15**, 507-515.
https://doi.org/10.4236/crcm.2026.1511063

Received: October 30, 2026
Accepted: November 22, 2026
Published: November 25, 2026

Copyright © 2026 by author(s) and Scientific Research Publishing Inc.
This work is licensed under the Creative Commons Attribution International License (CC BY 4.0).
http://creativecommons.org/licenses/by/4.0/
Open Access

Abstract

Background: Dermoid cysts are benign developmental cysts that occur infrequently in the head and neck and are rarely reported in the preauricular area. Based on the similarity of this lesion to more frequent preauricular anomalies, histopathological examination is essential for accurate diagnosis. **Case presentation:** An 8-year-old child was evaluated for recurrent sore throat over the course of one year. Examination revealed enlarged tonsils and, as a result, a stable, chronic 1.4 cm polypoidal lesion with a sinus tract in the right preauricular region. The lesion was completely removed during the tonsillectomy surgery. Histopathology showed cystic spaces lined by benign stratified squamous epithelium keratinizing, with pilosebaceous structures attached to the cyst walls, alongside clusters of mature cartilage, adipose tissue, and skeletal muscle fibers in a disorganized configuration. No signs of cytological atypia or immature elements were present. A diagnosis of dermoid cyst with a cartilaginous component was established. At six months of follow-up, the wound had healed with a satisfactory scar, and there was no clinical evidence of recurrence. **Conclusions:** A dermoid cyst should be considered in the differential diagnosis of a preauricular polypoidal lesion with a sinus tract in pediatric patients; further consider an accessory tragus and preauricular sinus. Complete excision with

histological confirmation is a suitable treatment. Ultrasound or cross-sectional imaging should be considered prior to surgery to define the depth of the lesion.

Keywords

Dermoid Cyst, Preauricular Region, External Ear, Accessory Tragus, Preauricular Sinus, Pediatric Otolaryngology

1. Introduction

Dermoid cysts are benign embryonic cysts lined by squamous epithelium keratinizing, with skin appendages such as hair follicles and sebaceous glands in the cyst wall [1]. It is believed that they originate along embryonic fusion lines and commonly occur at the lateral angle of the eye and in the midline of the forehead, neck, and nose [1]. A dermoid cyst contains ectodermal and mesodermal components. This distinguishes it from a true teratoma, a germ-cell neoplasm that contains derivatives of one or more germ layers [2].

The head and neck account for approximately 7% of all dermoid cysts, with the eyebrow, head, and neck being the predominant locations in this region. Dermoid cysts of the ear and the periauricular area are rare [3] [4]. They have mostly been documented in individual case reports and limited series [5]-[11].

In children, a lesion anterior to the ear is more frequently a preauricular sinus or an accessory tragus. A dermoid cyst is not usually suspected preoperatively and is therefore diagnosed only post-excision. We report a youngster in whom a preauricular polypoidal lesion with a sinus tract was found incidentally. Histopathological examination revealed a dermoid cyst containing mature cartilage, adipose tissue, and skeletal muscle. We describe the findings, discuss how this lesion should be distinguished from the common preauricular anomalies, and review the relevant literature. This report follows the CARE guidelines [12] [13].

2. Case Presentation

2.1. Clinical Findings

An 8-year-old boy was brought by his parents to the outpatient clinic with recurrent sore throat over the preceding year. On examination, the tonsils were enlarged and inflamed. There was also a 1.4 cm polypoidal lesion with a sinus tract in the right preauricular area. According to the parents, the lesion had been present for a long time and had not changed in size. He exhibited no symptoms of pain, fever, discharge, or auditory impairment; there was no record of a recent ear infection; and there was no history of preauricular trauma or surgery. The personal and family background was unremarkable. The provisional clinical diagnosis was chronic tonsillitis with a preauricular sinus.

The abnormal tissue was surgically excised under local anesthesia. During the procedure, a clearly defined, encapsulated mass was observed, showing no connection to the surrounding bone or muscle. A cream-colored lesion, more cohesive than the adjacent tissues, was excised along with its capsule; however, a residual tract cannot be excluded. The operation proceeded without complications, and standard closure of the surgical site was performed.

2.2. Therapeutic Intervention

Bilateral tonsillectomy and full excision of the right preauricular lesion were conducted under general anaesthesia for diagnosis and treatment. The postoperative course was uneventful, and the excised preauricular tissue was sent for histopathological examination. There were no signs of recurrence or cosmetic results six months after the operation.

2.3. Histopathological Findings

The specimen was received in formalin as a "right preauricular lesion." It consisted of a single unoriented piece of tan-brown, irregular, polypoidal soft-to-firm tissue measuring 1.4 × 0.8 × 0.5 cm. It was submitted entirely in one cassette.

Haematoxylin and eosin (H&E) sections revealed mature tissues of several types in a haphazard arrangement. The dermal component formed cystic cavities lined by benign stratified squamous epithelium and filled with keratin (**Figure 1**, **Figure 2**). Pilosebaceous units were attached to the cyst walls (**Figure 3** and **Figure 4**). Mature cartilage islands and bony tissue were present (**Figures 1-3** and **Figure 5**), and mature adipocytes and skeletal muscle fibers were scattered between these components (**Figure 5**). No cytological atypia, mitotic activity, or immature component was seen. The diagnosis was a dermoid cyst with a cartilaginous element.

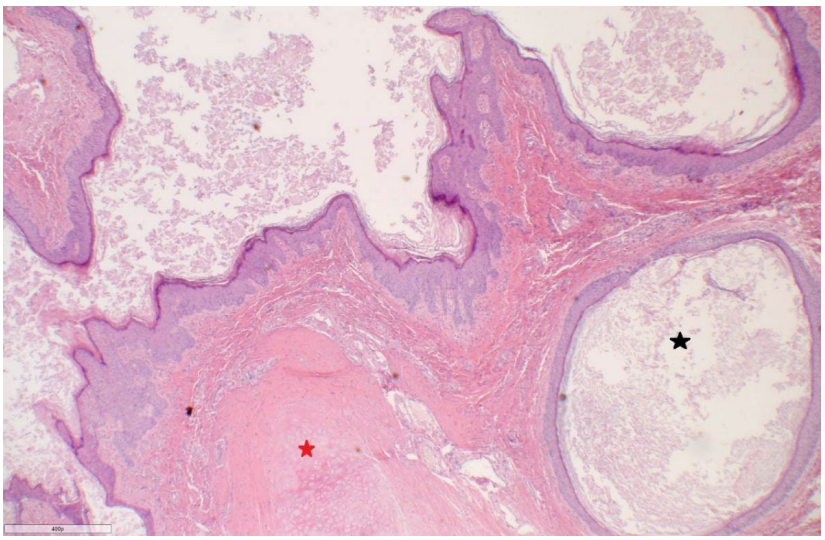

Figure 1. Cystic spaces lined by benign epithelium (black asterisk) and cartilage (red asterisk). H&E, ×400.

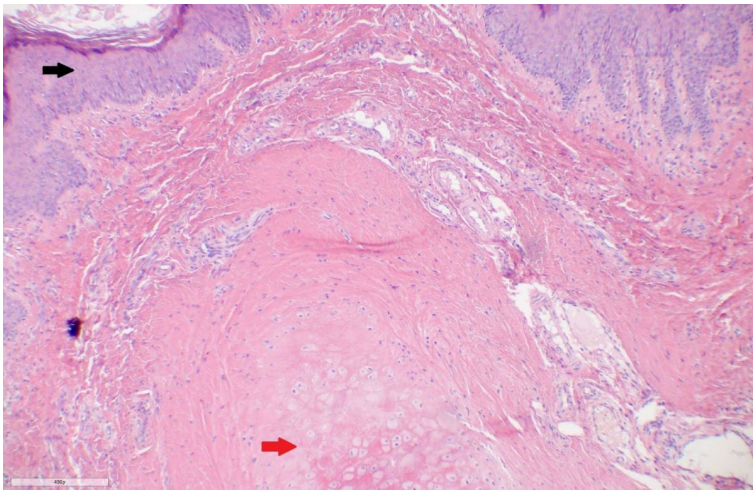

Figure 2. The cyst is lined by benign stratified keratinizing squamous epithelium (black arrow); mature cartilage (red arrow) is also seen. H&E, ×100.

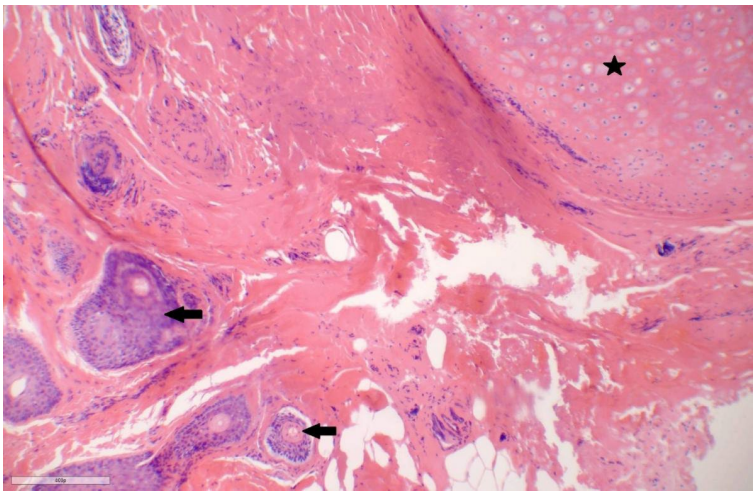

Figure 3. Hair follicles (black arrows) and cartilage (black asterisk). H&E, ×100.

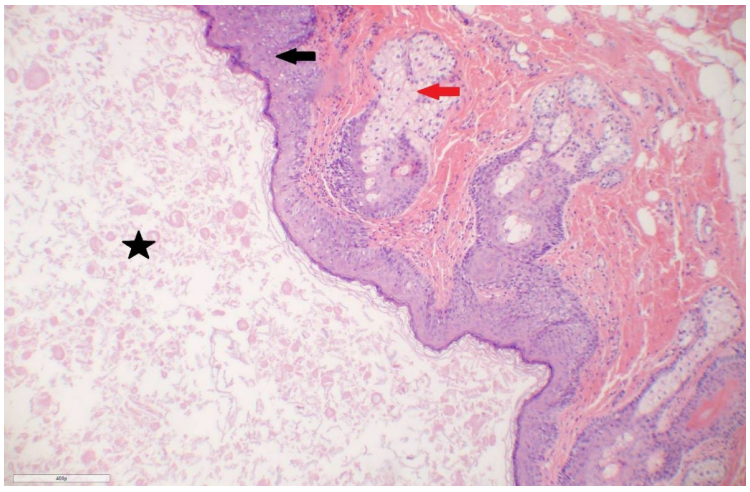

Figure 4. A keratin-filled cyst (black asterisk) lined by stratified squamous epithelium (black arrow), with a pilosebaceous unit attached to the wall (red arrow). H&E, ×100.

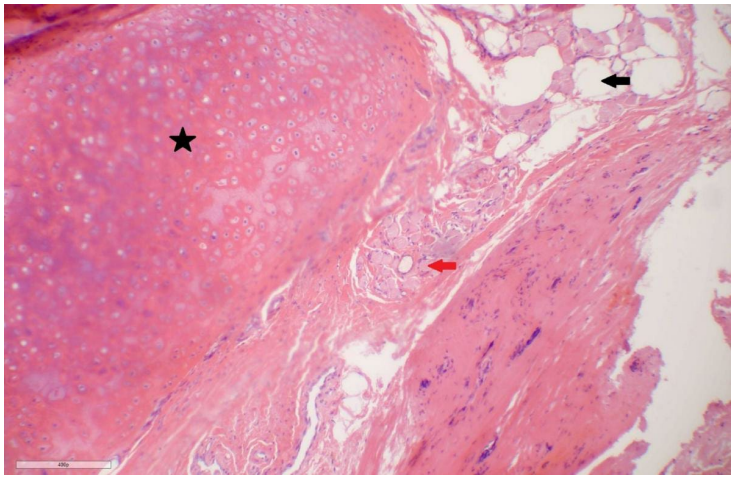

Figure 5. Mature cartilage (black asterisk), adipocytes (black arrow), and a focus interpreted as skeletal muscle fibers (red arrow). H&E, ×100.

3. Discussion

3.1. Terminology and Diagnostic Categorization

The terms "dermoid cyst" and "cystic teratoma" are occasionally utilized interchangeably; however, they describe different entities. A cutaneous dermoid cyst is a developing cyst whose wall contains epidermis and adnexa. A teratoma is a tumor that contains derivatives of one or more germ layers [2]; hence, the number of germ layers present does not distinguish it from a dermoid cyst. The differentiation is based on the nature of the lesion. In this specimen, the ectodermal and mesodermal tissues present (epidermis, adnexa, cartilage, fat) are all normally found in the preauricular region; the lesion was a superficial cystic polyp, and there were no tissues foreign to the site, no immature elements, and no atypia. These features indicate a dermoid cyst (choristoma) rather than a teratoma [14] [15]. On H&E morphology alone, a mature teratoma cannot be categorically excluded [14].

3.2. Differential Diagnosis

The primary differential diagnosis in this boy is an accessory tragus (auricular appendage), a prevalent developmental anomaly of the preauricular region that consists of skin and subcutaneous tissue and may contain a cartilage core, epidermal inclusion cyst, and dermoid cyst [14] [16]. It is only infrequently associated with further first branchial arch defects [16], and it can occasionally occur at atypical locations, as evidenced by a recent report of an oropharyngeal accessory tragus [17]. The distinction rests on the on many findings including: presence of the pilosebaceous units attached to the cyst wall (instead of the dermis) and presence of bony tissue & presence of skeletal muscle fibers in haphazardly way in the lesion. However, we acknowledge that the site, polypoid shape, the sinus tract, and the cartilage & fat remain compatible with an accessory tragus. Preauricular sinuses are a separate yet associated congenital abnormality of the same region. They are often sporadic or familial, and in 3% - 10% of cases they are related to other con-

ditions, mainly auditory loss and branchio-oto-renal disease [16]. In a recent retrospective analysis of 120 periauricular lesions, epidermoid cysts (21.7%) and preauricular sinus (37.5%) were the predominant causes, with congenital factors [18] [19]. A polypoidal, long-standing, stable preauricular lesion with a sinus tract could therefore be explained by this entity, with an associated epidermal cyst.

Other histopathological diagnoses for preauricular and postauricular lesions include epidermal inclusion cyst, pilar cyst, branchial cleft cyst, lipoma exhibiting cystic degeneration, schwannoma with cystic alterations, adnexal tumors, reactive lymphadenopathy, and malignant cutaneous neoplasms, including squamous cell carcinoma [9]. An epidermal inclusion cyst lacks adnexa and additional mesenchymal components in the wall. A pilar cyst lacks the heterogeneous tissue elements observed. A branchial cleft cyst is generally lined by squamous or respiratory epithelium with lymphoid tissue within its wall. No evidence of malignancy in the examined sections.

3.3. Pathogenesis

The exact etiology of cutaneous dermoid cysts is not fully understood. Three mechanisms have been suggested: first, congenital sequestration of ectodermal skin components along embryonic lines of fusion. Second, postnatal embedding of epidermal elements into deeper tissue after injury, with subsequent proliferation and keratinization. Third, development from residual totipotent cells within the dermis of skin [1]. The congenital explanation is preferred for lesions evident from early childhood, as in this patient. The presence of deep-lying cartilage in this instance is an unusual observation in a dermoid cyst, potentially indicative of the complex embryology of the first and second branchial arches and the auricle.

3.4. Clinical Features and Epidemiological Aspects

Individuals of both genders and various age groups have been reported to have dermoid cysts in the preauricular and postauricular regions [7] [10]. Patients frequently arrive for treatment at a delayed stage. The provided justifications are slow growth, enlargement or pain, and a wish for cosmetic improvement [11]. Previous studies have reported a minimal number of lesions in this region. For instance, older series suggest how uncommon the site is. For example, a 1937 analysis of 1495 patients reported no postauricular dermoid cyst [18].

3.5. Investigation and Management

Histopathological examination confirms the diagnosis. Although preoperative ultrasound is useful to assess depth and content, CT or MRI is advised when there is suspicion of a deep element, bone involvement, or connection to the parotid or intracranial structures, particularly in dermoid cysts in other head and neck locations. Complete surgical excision is the therapeutic option of choice and mitigates the risks of recurrence, infection, and rupture [3] [4] [10]. Excision in childhood

yields the best cosmetic result [4]. If the lesion possesses a sinus tract, the tract should be followed and excised completely.

Malignant transformation in a dermoid cyst has been reported solely as isolated case reports, predominantly in subcutaneous [19], sublingual [20], and intracranial lesions [21]. It has not been described in any known preauricular lesion. Chronic inflammation has been suggested as a potential contributor, yet the suggestion is speculative. The risk is extremely low and should not be used to justify urgent surgery. But it serves as a reason to submit every removed lesion for histopathological examination.

4. Limitations

This is a single case report. Preoperative imaging was unavailable, follow-up lasted six months, and no immunohistochemical or specialized stains were conducted. The diagnosis depends only on H&E morphology, and an accessory tragus with a related cyst cannot be excluded with complete certainty. Recurrence was assessed clinically, without imaging.

5. Conclusion

A dermoid cyst needs to be considered when a pediatric patient has a preauricular polypoidal lesion with a sinus tract, although accessory tragus and preauricular sinus are much more prevalent. All excised lesions should be histopathologically examined, and imaging should be considered when the depth of the lesion is uncertain. Complete excision is therapeutic in the cases reported so far. Histology alone may not reliably separate it from an accessory tragus with an inclusion cyst.

Patient Consent

Informed consent for publication of this case and images was obtained from the patient's parents.

Acknowledgements

The researchers would like to thank the Deanship of Graduate Studies and Scientific Research at Qassim University (https://www.qu.edu.sa/).

Author Contributions

ASA and AYB contributed to the methodology, conception, and discussion. FAA, ASA, HHA, and KAA conducted data analysis and investigation. YAA, AAA, and NAA prepared the original draft. MAA and AAA reviewed and edited the content, and ASA provided supervision. All authors read, reviewed, edited, and approved the final manuscript.

Conflicts of Interest

The authors declare no conflicts of interest regarding the publication of this paper.

References

[1] Weedon, D. (2010) Cysts, Sinuses, and Pits. In: *Weedon's Skin Pathology*, Elsevier, 441-457.e9. https://doi.org/10.1016/b978-0-7020-3485-5.00017-6

[2] Salzillo, C., Imparato, A., Fortarezza, F., Maniglio, S., Lucà, S., La Verde, M., *et al.* (2024) Gonadal Teratomas: A State-of-the-Art Review in Pathology. *Cancers*, **16**, Article No. 2412. https://doi.org/10.3390/cancers16132412

[3] Pollard, Z.F., Harley, R.D. and Calhoun, J. (1976) Dermoid Cysts in Children. *Pediatrics*, **57**, 379-382. https://doi.org/10.1542/peds.57.3.379

[4] Orozco-Covarrubias, L., Lara-Carpio, R., Saez-de-Ocariz, M., Duran-Mckinster, C., Palacios-Lopez, C. and Ruiz-Maldonado, R. (2013) Dermoid Cysts: A Report of 75 Pediatric Patients. *Pediatric Dermatology*, **30**, 706-711. https://doi.org/10.1111/pde.12080

[5] Horikiri, M., Ueda, K. and Kato, M. (2014) Dermoid Cyst of the Auricle: A Rare Manifestation. *BMJ Case Reports*, **2014**, bcr2014205826. https://doi.org/10.1136/bcr-2014-205826

[6] Kathuria, B., Dhingra, H., Arora, M. and Rana, D. (2020) Post-Auricular Dermoid Cyst-Uncommon Lesion at an Uncommon Site. *International Journal of Otorhinolaryngology and Head and Neck Surgery*, **6**, Article 1374. https://doi.org/10.18203/issn.2454-5929.ijohns20202798

[7] Aljeaid, D., Alharthi, A., Alotaibi, O. and Altalhi, W. (2022) Postauricular Dermoid Cyst: A Rare Lesion in an Extremely Rare Location. *The Egyptian Journal of Otolaryngology*, **38**, Article No. 92. https://doi.org/10.1186/s43163-022-00289-9

[8] Shankar, D.U., Sarmaik, D.A. and Kumari, D.R. (2020) Rare Occurrence of Dermoid Cyst in Postauricular Region: A Case Report. *International Journal of Scientific and Research Publications*, **10**, 509-511. https://doi.org/10.29322/ijsrp.10.05.2020.p10157

[9] Yogesh, T.L., Anjani Kumar, J., Devatwisha, G. and Aggi Susan, S. (2016) Postauricular Dermoid Cyst: A Case Report. *IOSR Journal of Dental and Medical Sciences*, **15**, 99-102.

[10] Alahmadi, E.A., Alhusayni, R.A., Albeladi, M.A. and Naseer, S.N. (2026) A Rare Presentation of a Postauricular Dermoid Cyst: A Case Report and Literature Review. *Cureus*, **18**, e107113. https://doi.org/10.7759/cureus.107113

[11] Mohammed, A. and Abdullahi, K. (2018) Postauricular Epidermoid and Dermoid Cysts in Adults. *The Egyptian Journal of Otolaryngology*, **34**, 213-216. https://doi.org/10.4103/ejo.ejo_33_18

[12] Riley, D.S., Barber, M.S., Kienle, G.S., Aronson, J.K., von Schoen-Angerer, T., Tugwell, P., *et al.* (2017) CARE Guidelines for Case Reports: Explanation and Elaboration Document. *Journal of Clinical Epidemiology*, **89**, 218-235. https://doi.org/10.1016/j.jclinepi.2017.04.026

[13] Gagnier, J.J., Kienle, G., Altman, D.G., Moher, D., Sox, H. and Riley, D. (2013) The CARE Guidelines: Consensus-Based Clinical Case Reporting Guideline Development. *Journal of Medical Case Reports*, **7**, Article No. 223. https://doi.org/10.1186/1752-1947-7-223

[14] Cong, L., Wang, S., Yeung, S.Y., Lee, J.H.S., Chung, J.P.W. and Chan, D.Y.L. (2023) Mature Cystic Teratoma: An Integrated Review. *International Journal of Molecular Sciences*, **24**, Article 6141. https://doi.org/10.3390/ijms24076141

[15] Sebben, J.E. (1989) The Accessory Tragus—No Ordinary Skin Tag. *The Journal of Dermatologic Surgery and Oncology*, **15**, 304-307. https://doi.org/10.1111/j.1524-4725.1989.tb03164.x

[16] Husman, T., Benjamin, T., Patel, E.J., Akanuma, N., Pigal, A. and Cheng, Y.S. (2025) An Oropharyngeal Accessory Tragus in a Young Patient with Conductive Hearing Loss. *Clinical Case Reports*, **13**, e70019. https://doi.org/10.1002/ccr3.70019

[17] Scheinfeld, N.S., Silverberg, N.B., Weinberg, J.M. and Nozad, V. (2004) The Preauricular Sinus: A Review of Its Clinical Presentation, Treatment, and Associations. *Pediatric Dermatology*, **21**, 191-196. https://doi.org/10.1111/j.0736-8046.2004.21301.x

[18] Ahmed, M.E., Abdelhamed, A., Al-Amaragy, A., Badry, M.S. and Hussein, M.A. (2026) The Superficial Lesions in the Periauricular Region: A Retrospective Study. *Journal of Maxillofacial and Oral Surgery*, **25**, 767-773. https://doi.org/10.1007/s12663-024-02160-1

[19] Stephenson, G.C. and Ironside, J.W. (1991) Squamous Cell Carcinoma Arising in a Subcutaneous Dermoid Cyst. *Postgraduate Medical Journal*, **67**, 84-86. https://doi.org/10.1136/pgmj.67.783.84

[20] Devine, J.C. and Jones, D.C. (2000) Carcinomatous Transformation of a Sublingual Dermoid Cyst. *International Journal of Oral and Maxillofacial Surgery*, **29**, 126-127. https://doi.org/10.1016/s0901-5027(00)80009-0

[21] Tsugu, H., Fukushima, T., Hayashi, S., Iwaasa, M. and Matsuda, T. (2001) Squamous Cell Carcinoma Arising in an Intracranial Dermoid Cyst. Case Report. *Neurologia Medico-Chirurgica*, **41**, 213-216. https://doi.org/10.2176/nmc.41.213