Scientific Research Publishing

Case Reports in Clinical Medicine, 2026, 15(11), 495-506
https://www.scirp.org/journal/crcm
ISSN Online: 2325-7083
ISSN Print: 2325-7075

Meningothelial Meningioma Radiologically Mimicking a High-Grade Glioma: A Case Report and Literature Review

Estefania Ramírez-Medina[1*], Angélica F. Ramos-Rodarte[1], Fabrizio A. Mortola-Rodríguez[2*], Carlos Fernando Estrella-Sánchez[2], Lorena Gómez-Loza[2], José Eduardo Padilla-Aceves[2]

[1]University Center for Health Sciences, University of Guadalajara, Guadalajara, Mexico
[2]Department of Neurosurgery "Dr. Salvador González Cornejo", OPD Fray Antonio Alcalde Civil Hospital of Guadalajara, Guadalajara, Mexico
Email: *neurodocfab@gmail.com, *estefaniaramed@gmail.com

How to cite this paper: Ramírez-Medina, E., Ramos-Rodarte, A.F., Mortola-Rodríguez, F.A., Estrella-Sánchez, C.F., Gómez-Loza, L. and Padilla-Aceves, J.E. (2026) Meningothelial Meningioma Radiologically Mimicking a High-Grade Glioma: A Case Report and Literature Review. *Case Reports in Clinical Medicine*, **15**, 495-506.
https://doi.org/10.4236/crcm.2026.1511062

Received: April 17, 2026
Accepted: November 22, 2026
Published: November 25, 2026

Copyright © 2026 by author(s) and Scientific Research Publishing Inc.
This work is licensed under the Creative Commons Attribution International License (CC BY 4.0).
http://creativecommons.org/licenses/by/4.0/

Open Access

Abstract

Meningiomas are the most common primary tumors of the central nervous system and typically exhibit characteristic radiological features reflecting their extra-axial origin. However, certain histological variants may present with atypical imaging patterns that resemble aggressive intra-axial neoplasms, making preoperative diagnosis challenging. We report the case of a 28-year-old woman who presented with progressive headache and visual deterioration. Brain magnetic resonance imaging revealed a heterogeneous right occipital lesion with solid and cystic components, irregular contrast enhancement, extensive peritumoral vasogenic edema, and significant mass effect, findings highly suggestive of a high-grade glioma. Surgical resection was performed through a minimally invasive parieto-occipital approach. Intraoperatively, the lesion was relatively well circumscribed, with heterogeneous solid and cystic components. Histopathological examination confirmed a meningothelial meningioma, World Health Organization (WHO) grade 1, with microcystic changes and hyaline degeneration. Immunohistochemical analysis demonstrated positivity for epithelial membrane antigen (EMA), supporting the diagnosis. The postoperative course was favorable, with no new neurological deficits. Certain meningioma variants may exhibit cystic changes, heterogeneous enhancement, and extensive peritumoral edema, producing imaging characteristics that overlap with those of high-grade gliomas and metastatic lesions. These features may obscure their typical extra-axial appearance and suggest an infiltrative growth pattern. Although pronounced peritumoral edema may reflect increased tumor-related biological activity, it does not necessarily correlate with a higher histological grade. This case highlights the radiological variability of WHO grade 1 menin-

gothelial meningiomas and the potential discrepancy between imaging findings and histopathological diagnosis. Recognizing these atypical presentations and integrating clinical, radiological, and histopathological findings are essential to establishing diagnostic accuracy, avoiding misclassification, and guiding appropriate neurosurgical management.

Keywords

Meningothelial Meningioma, Atypical Radiological Presentation, Extra-Axial Tumor with Intra-Axial Appearance, High-Grade Glioma Differential Diagnosis, Solid-Cystic Brain Lesion, Neuro-Oncology

1. Introduction

Meningiomas are the most common primary non-glial intracranial neoplasms, accounting for approximately one-third of all primary central nervous system (CNS) tumors. They originate from meningothelial (arachnoid cap) cells and exhibit a broad spectrum of biological behavior, ranging from indolent lesions to tumors with aggressive growth and recurrence potential. According to the 2021 World Health Organization (WHO) Classification of Tumors of the Central Nervous System (CNS5), meningiomas are classified into three histological grades (CNS WHO grades 1 - 3), based on mitotic activity, histopathological features, brain invasion, and specific molecular alterations. Grade 1 tumors represent the majority of cases and generally have a favorable prognosis following surgical resection, although recurrence may occur even after apparently complete removal [1] [2]. Recent molecular studies have further demonstrated that meningiomas comprise biologically distinct subgroups with different clinical outcomes, highlighting the limitations of relying exclusively on histological grading to predict tumor behavior [3] [4]. Genomic investigations have also identified recurrent alterations involving genes such as TRAF7, KLF4, AKT1, and SMO, providing additional insight into the molecular heterogeneity of these tumors [5] [6]. Despite their predominantly benign nature, considerable heterogeneity in morphology, molecular profile, growth patterns, and radiological presentation may complicate preoperative assessment and treatment planning.

From a neuroradiological perspective, conventional meningiomas typically appear as well-circumscribed extra-axial masses with broad dural attachment and avid, predominantly homogeneous contrast enhancement on magnetic resonance imaging (MRI). Additional findings supporting their extra-axial origin include the cerebrospinal fluid (CSF) cleft sign, displacement of adjacent cortical structures, and an enhancing dural tail. Computed tomography (CT) may further demonstrate intratumoral calcifications, adjacent hyperostosis, or osseous remodeling. Although these findings are highly suggestive of meningioma, none is independently pathognomonic, and their absence does not exclude the diagnosis. MRI remains the preferred imaging modality for evaluating tumor location, anatomical relation-

ships, vascular involvement, and potential extension into adjacent structures. Nevertheless, conventional imaging findings do not always reliably predict the underlying histological subtype or biological grade [7] [8].

Atypical radiological presentations constitute an important diagnostic challenge, particularly when meningiomas exhibit heterogeneous signal intensity, irregular contrast enhancement, indistinct tumor-brain interfaces, cystic components, or extensive peritumoral edema. These findings may obscure the characteristic extra-axial features and suggest an intra-axial origin, broadening the differential diagnosis to include high-grade gliomas and metastatic lesions [7] [9]. Cystic meningiomas are particularly challenging because their solid and fluid-containing components may produce complex imaging patterns resembling necrotic or cystic malignant tumors.

Nauta *et al.* initially described different configurations of cystic lesions associated with meningiomas, distinguishing intratumoral from peritumoral cystic components according to their anatomical relationship with the tumor and adjacent brain parenchyma [10]. Subsequent studies expanded the understanding of these lesions and proposed additional classifications based on their radiological and histopathological characteristics [11] [12]. Proposed mechanisms of cyst formation include degenerative changes, ischemic processes, intratumoral hemorrhage, fluid secretion, and entrapment of CSF. The coexistence of cystic components, heterogeneous enhancement, and mass effect may substantially increase diagnostic uncertainty, occasionally resulting in an incorrect preoperative diagnosis of high-grade glioma [13] [14].

Peritumoral brain edema (PTBE) represents another important imaging feature that may contribute to diagnostic uncertainty. Although frequently associated with high-grade intra-axial neoplasms, vasogenic edema is also commonly observed in meningiomas and may occasionally be disproportionate to tumor size. Its development is multifactorial and has been associated with increased vascular permeability, disruption of the blood-brain barrier, venous drainage impairment, and interactions between tumor tissue and adjacent cerebral parenchyma [15] [16]. Angiogenic mediators, particularly vascular endothelial growth factor (VEGF), as well as matrix metalloproteinases (MMPs), have been implicated in the development and severity of peritumoral edema through their effects on vascular permeability and extracellular matrix remodeling [17] [18]. Although extensive edema may reflect alterations in tumor vascularity and the tumor-brain interface, it does not necessarily indicate a higher histological grade or malignant behavior. This distinction is clinically relevant because pronounced edema and mass effect may create an appearance of radiological aggressiveness that does not correspond to the underlying histopathological diagnosis [19] [20].

Histopathologically, meningiomas comprise several morphological subtypes, including meningothelial, fibrous, transitional, angiomatous, secretory, and microcystic variants, among others. The meningothelial subtype is characterized by syncytial arrangements of polygonal cells with indistinct cytoplasmic borders, oval

nuclei, and occasional intranuclear pseudoinclusions. Microcystic meningioma, in contrast, represents a distinct WHO-recognized morphological subtype characterized by prominent microcyst formation, vacuolated cells, and intervening loose or myxoid stroma [21]. These morphological features may contribute to heterogeneous signal intensity and unusual enhancement patterns on MRI. Importantly, focal microcystic changes and degenerative alterations may also occur within other meningioma subtypes and should not automatically be interpreted as a distinct microcystic histological subtype [22].

Immunohistochemistry provides additional diagnostic support, particularly when morphological findings or radiological features overlap with those of other intracranial neoplasms. Epithelial membrane antigen (EMA) and somatostatin receptor 2A (SSTR2A) are commonly expressed in meningiomas and are useful markers in their differential diagnosis. Vimentin and progesterone receptor expression may provide further supportive evidence, whereas glial fibrillary acidic protein (GFAP) is generally absent in conventional meningioma cells. The combined interpretation of morphological and immunohistochemical findings is, therefore, essential for distinguishing meningiomas from glial, mesenchymal, and other intracranial neoplasms [23].

Surgical resection remains the primary treatment for symptomatic or radiologically progressive meningiomas, with the objective of achieving maximal safe tumor removal while preserving neurological function. Current management recommendations emphasize individualized treatment decisions based on clinical presentation, tumor characteristics, and anatomical location [24]. The extent of resection, traditionally assessed using the Simpson grading system, is an important prognostic factor associated with tumor recurrence, although histological grade, molecular characteristics, and anatomical location also influence long-term outcomes [25] [26].

Accordingly, accurate preoperative characterization is essential for surgical planning and appropriate therapeutic decision-making. When atypical meningiomas are mistaken for high-grade intra-axial neoplasms, diagnostic uncertainty may influence the selection of surgical strategies and subsequent management. Recognizing these uncommon radiological presentations and establishing a correlation between imaging, intraoperative findings, and histopathological characteristics are therefore fundamental to avoiding diagnostic pitfalls. In this context, we present a case of a WHO grade 1 meningothelial meningioma with microcystic changes and hyaline degeneration that exhibited atypical radiological features strongly suggestive of a high-grade intra-axial neoplasm, highlighting the diagnostic implications of this uncommon presentation.

2. Clinical Case

A 28-year-old woman presented with a two-month history of progressive right-sided hemicranial headache, described as stabbing in nature and reaching an intensity of 9/10 on the visual analog scale. The pain was intermittent, predomi-

nantly localized to the right side of the head, and partially responsive to analgesic medication. No associated nausea, vomiting, photophobia, or positional exacerbation was reported. During the first weeks of symptom progression, the headache gradually increased in frequency and intensity, prompting further medical evaluation. Approximately six weeks after symptom onset, the patient began experiencing intermittent diplopia and episodes of blurred vision, predominantly in the morning. She also reported delayed recovery of visual acuity following these episodes, suggesting progressive visual pathway dysfunction in the setting of an underlying intracranial space-occupying lesion.

Ophthalmological evaluation revealed mild optic disc pallor and decreased visual field sensitivity, raising suspicion of optic pathway involvement. These findings prompted referral to the Neurosurgery Department for further assessment. On neurological examination, the patient was alert, oriented, and cooperative, with no evidence of motor or sensory deficits. Cranial nerve examination was otherwise unremarkable, and cerebellar function was preserved. No additional focal neurological abnormalities were identified. Fundoscopic examination confirmed optic disc pallor, consistent with optic neuropathy. Given the progressive nature of the symptoms and the documented ophthalmological abnormalities, neuroimaging was indicated to investigate a possible intracranial compressive or infiltrative process.

Preoperative brain magnetic resonance imaging (MRI) demonstrated a heterogeneous lesion in the right parieto-occipital region, characterized by solid and cystic components, irregular peripheral contrast enhancement, extensive surrounding vasogenic edema, and associated mass effect. The axial T1-weighted post-contrast image revealed the heterogeneous architecture of the lesion, with irregular peripheral enhancement, distinct solid and cystic components, and prominent surrounding edema (**Figure 1(A)**). The sagittal T1-weighted post-contrast image further demonstrated its parieto-occipital location, ring-like enhancement, cystic component, and mass effect on the adjacent cerebral parenchyma (**Figure 1(B)**). The combination of heterogeneous enhancement, cystic degeneration, and extensive peritumoral edema raised strong suspicion of a high-grade intra-axial neoplasm, particularly a high-grade glioma. However, despite its aggressive radiological appearance, the lesion exhibited relatively well-defined margins and appeared to displace the adjacent cerebral parenchyma rather than demonstrate unequivocal infiltrative growth. No intralesional hemorrhagic component was identified. The atypical combination of imaging characteristics made definitive preoperative characterization challenging.

Following multidisciplinary evaluation, surgical resection was recommended based on the progressive clinical presentation, associated mass effect, and concern for an aggressive intracranial neoplasm. A right parieto-occipital craniotomy was performed using a minimally invasive microsurgical approach, with the objective of achieving adequate tumor exposure while minimizing disruption of the surrounding functional brain tissue. During the initial surgical exposure, the superior

occipital gyrus appeared enlarged, tense, and mildly pale compared with the adjacent cortical surface. A prominent cortical bulge corresponding to the underlying lesion was identified. Further inspection revealed a well-circumscribed, rounded subcortical lesion with displacement of the surrounding cortical vasculature (**Figure 2(A)**).

Upon progressive exposure, the tumor exhibited heterogeneous consistency, comprising firm solid areas and cystic components. Although preoperative imaging had suggested an intra-axial neoplasm, intraoperative inspection demonstrated a relatively well-defined interface between the lesion and the adjacent cerebral parenchyma, without apparent macroscopic evidence of diffuse infiltration. Careful microsurgical dissection was undertaken, including subpial dissection, to progressively expose the tumor while preserving the surrounding cortical structures and minimizing injury to adjacent tissue (**Figure 2(B)**). The lesion was subsequently removed, achieving gross total resection. Meticulous hemostasis was performed, and no intraoperative complications were encountered.

Postoperatively, the patient was transferred to the postoperative care unit for neurological monitoring. Her postoperative course was uneventful, and she remained hemodynamically stable, with preserved neurological function and no new focal deficits. Early postoperative brain MRI confirmed gross total resection of the lesion, demonstrating expected postoperative changes and a reduction in the associated mass effect. No immediate postoperative neurological complications were documented. The patient continued to recover satisfactorily and was discharged on postoperative day seven with recommendations for outpatient neurosurgical follow-up, serial neuroimaging, and comprehensive neuro-ophthalmological reassessment.

Histopathological examination revealed a meningothelial neoplasm composed predominantly of uniform polygonal cells with oval nuclei and indistinct cytoplasmic borders, arranged in solid sheets and syncytial patterns. The tumor also exhibited focal stromal hyalinization, characterized by areas of eosinophilic extracellular material (**Figure 3(A)**). Additionally, prominent microcystic changes were identified, consisting of multiple variably sized cystic spaces interspersed throughout the tumor tissue, with preservation of the underlying meningothelial cellular architecture (**Figure 3(B)**). These morphological findings were consistent with a meningothelial meningioma, World Health Organization (WHO) grade 1, exhibiting focal microcystic changes and hyaline degeneration. Immunohistochemical analysis demonstrated positive epithelial membrane antigen (EMA) expression, further supporting the meningothelial origin of the lesion and confirming the histopathological diagnosis.

At the one-month postoperative follow-up, the patient reported substantial improvement in headache intensity and frequency. Visual symptoms had also improved, with partial recovery of visual acuity. No new neurological deficits or surgery-related complications were identified. Given the benign histopathological classification and the achievement of gross total resection, continued clinical and radiological surveillance was recommended, together with serial neuro-ophthal-

mological evaluations to assess the extent of visual recovery and monitor for potential tumor recurrence.

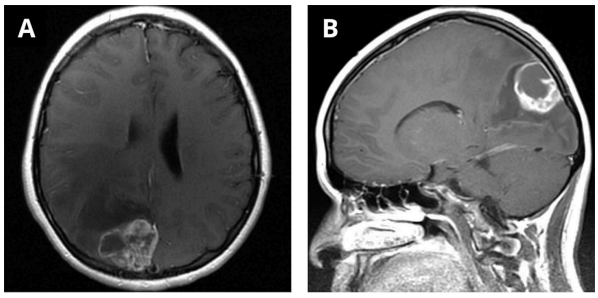

Figure 1. Preoperative contrast-enhanced brain magnetic resonance imaging (MRI). (A) Axial T1-weighted post-contrast image demonstrating a heterogeneous right posterior cerebral lesion with irregular peripheral enhancement, solid and cystic components, and surrounding vasogenic edema. (B) Sagittal T1-weighted post-contrast image showing the lesion in the parieto-occipital region, with heterogeneous ring-like enhancement, a cystic component, and associated mass effect.

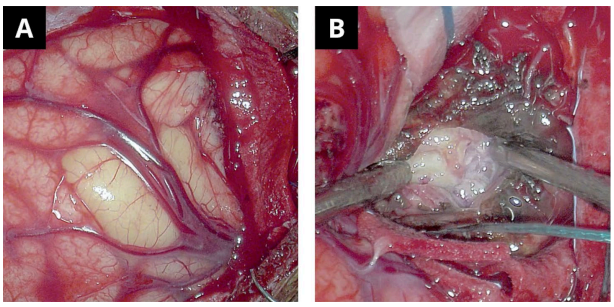

Figure 2. Intraoperative microscopic views during tumor resection. (A) Exposure of the right parieto-occipital cortical surface, revealing a well-circumscribed, rounded subcortical lesion with prominent cortical bulging and displacement of the surrounding cortical vasculature. (B) Intraoperative photograph following cortical and subpial dissection, demonstrating progressive exposure of the tumor, its solid component, and the interface with the adjacent cerebral parenchyma during microsurgical resection.

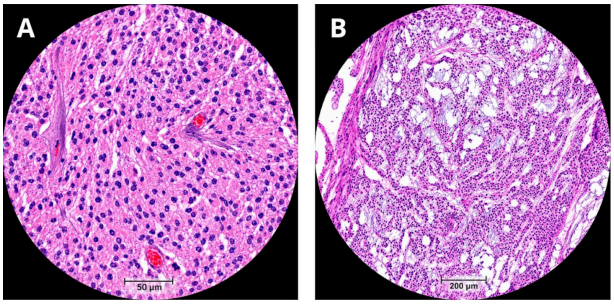

Figure 3. Histopathological features of the tumor (hematoxylin and eosin staining). (A) High-power view showing a predominantly solid meningothelial growth pattern, composed of uniform polygonal cells with oval nuclei and indistinct cytoplasmic borders, accompanied by focal stromal hyalinization (scale bar = 50 μm). (B) Low-power view demonstrating prominent microcystic changes, characterized by multiple variably sized cystic spaces interspersed within the tumor tissue, with preserved areas of meningothelial cell proliferation (scale bar = 200 μm).

3. Discussion

This case illustrates the diagnostic challenge posed by meningiomas with atypical radiological features that closely resemble high-grade intra-axial neoplasms. Although meningiomas typically present as well-circumscribed extra-axial masses with relatively homogeneous enhancement, certain variants may exhibit heterogeneous enhancement, cystic components, and extensive peritumoral edema, complicating their preoperative identification [6] [8]. In our patient, the combination of a heterogeneous right parieto-occipital lesion, solid and cystic components, irregular peripheral enhancement, and marked vasogenic edema strongly suggested a high-grade glioma. These findings demonstrate how atypical meningiomas may depart from their conventional imaging appearance and create substantial diagnostic uncertainty.

The cystic component was particularly relevant to the radiological presentation. Cystic meningiomas are uncommon and may display variable imaging patterns depending on the location and characteristics of the cystic spaces, including their relationship with the tumor and adjacent brain parenchyma [9] [13]. In this case, the coexistence of solid and cystic components contributed to the heterogeneous appearance and reinforced the initial suspicion of an aggressive intra-axial neoplasm. However, the relatively well-defined margins and displacement of the surrounding parenchyma were findings that, in retrospect, suggested a more circumscribed growth pattern.

Another important feature was the extensive peritumoral edema. Although this finding may be associated with tumor size, location, histological characteristics, and biological aggressiveness, it is not specific for malignant behavior [14]. Previous studies have implicated several mechanisms in its development, including pial vascular supply, venous drainage obstruction, altered hydrodynamic processes, and increased vascular permeability [15] [17]. Additionally, vascular endothelial growth factor expression and matrix metalloproteinase activity have been associated with edema formation in meningiomas [18] [20]. In our patient, the marked edema should therefore be interpreted as a manifestation of complex tumor-brain interactions rather than as independent evidence of high-grade histology.

Histopathological examination ultimately established the diagnosis of meningothelial meningioma, CNS WHO grade 1, with focal microcystic changes and hyaline degeneration. The presence of multiple variably sized microcystic spaces and focal stromal hyalinization provides a histological context for the heterogeneous imaging appearance. Microcystic meningiomas may exhibit prominent peritumoral edema and atypical radiological characteristics despite their classification as WHO grade 1 tumors [7] [26]. EMA positivity further supported meningothelial differentiation, highlighting the importance of immunohistochemistry when establishing the diagnosis and distinguishing meningiomas from their histological mimics [21].

The intraoperative findings further contributed to resolving the diagnostic discrepancy. Unlike the infiltrative appearance initially suspected on MRI, the lesion was relatively well circumscribed, with displacement of the cortical vasculature and a discernible interface with the adjacent parenchyma, without mac-

roscopic evidence of diffuse infiltration. Gross total resection was achieved, and the patient experienced an uncomplicated postoperative course, with substantial improvement in headache and partial recovery of visual acuity at one-month follow-up. Although long-term surveillance is necessary, these early findings support a favorable initial clinical outcome. The extent of resection remains an important consideration in meningioma management and has historically been associated with recurrence risk and postoperative prognosis [20] [23].

Overall, this case demonstrates that the combination of cystic changes, irregular enhancement, and extensive vasogenic edema can cause a benign meningothelial meningioma to closely mimic a high-grade glioma. The discrepancy between the preoperative imaging, intraoperative appearance, and definitive histopathological diagnosis emphasizes that radiological features alone cannot reliably establish tumor grade or biological behavior. Careful integration of imaging, surgical findings, histopathology, and immunohistochemistry is essential to achieve diagnostic accuracy and guide appropriate management.

4. Conclusion

Meningiomas with atypical imaging features may represent a significant diagnostic challenge, particularly when their appearance suggests an aggressive intra-axial neoplasm. This case demonstrates that the combination of cystic changes, irregular contrast enhancement, and extensive peritumoral edema may obscure the underlying benign histology of a meningothelial meningioma. The correlation between radiological, intraoperative, and histopathological findings was essential to establish the definitive diagnosis and characterize the lesion accurately. Awareness of these atypical presentations may help prevent diagnostic misinterpretation and support appropriate surgical decision-making, avoiding assumptions of malignancy based solely on imaging findings.

Ethical Considerations

The authors declare that all procedures performed in this study were conducted in accordance with institutional and international ethical standards for research involving human subjects. Written informed consent for publication of clinical data and imaging was obtained from the patient. All identifying information has been removed to ensure patient anonymity. According to institutional policy, formal ethics committee approval was not required for the publication of this single-patient case report.

Acknowledgements

The authors thank the Neurosurgery Department for their valuable support in the diagnosis and management of this case.

Declaration

ChatGPT (version 5.5) was used for language polishing and grammar correction

of this manuscript.

Author Contributions

All authors contributed equally to the conception, development, literature review, data collection, analysis and interpretation, and writing of this manuscript. All authors participated in the critical revision of the manuscript, approved the final version, and agree to be accountable for all aspects of the work.

Conflicts of Interest

The authors declare no conflicts of interest regarding the publication of this paper.

References

[1] Louis, D.N., Perry, A., Wesseling, P., Brat, D.J., Cree, I.A., Figarella-Branger, D., *et al.* (2021) The 2021 WHO Classification of Tumors of the Central Nervous System: A Summary. *Neuro-Oncology*, **23**, 1231-1251. https://doi.org/10.1093/neuonc/noab106

[2] Soni, N., Ora, M., Bathla, G., Szekeres, D., Desai, A., Pillai, J.J., *et al.* (2025) Meningioma: Molecular Updates from the 2021 World Health Organization Classification of CNS Tumors and Imaging Correlates. *American Journal of Neuroradiology*, **46**, 240-250. https://doi.org/10.3174/ajnr.a8368

[3] Nassiri, F., Liu, J., Patil, V., Mamatjan, Y., Wang, J.Z., Hugh-White, R., *et al.* (2021) A Clinically Applicable Integrative Molecular Classification of Meningiomas. *Nature*, **597**, 119-125. https://doi.org/10.1038/s41586-021-03850-3

[4] Sahm, F., Schrimpf, D., Stichel, D., Jones, D.T.W., Hielscher, T., Schefzyk, S., *et al.* (2017) DNA Methylation-Based Classification and Grading System for Meningioma: A Multicentre, Retrospective Analysis. *The Lancet Oncology*, **18**, 682-694. https://doi.org/10.1016/s1470-2045(17)30155-9

[5] Clark, V.E., Erson-Omay, E.Z., Serin, A., Yin, J., Cotney, J., Özduman, K., *et al.* (2013) Genomic Analysis of Non-NF2 Meningiomas Reveals Mutations in TRAF7, KLF4, AKT1, and SMO. *Science*, **339**, 1077-1080. https://doi.org/10.1126/science.1233009

[6] Brastianos, P.K., Horowitz, P.M., Santagata, S., Jones, R.T., McKenna, A., Getz, G., *et al.* (2013) Genomic Sequencing of Meningiomas Identifies Oncogenic SMO and AKT1 Mutations. *Nature Genetics*, **45**, 285-289. https://doi.org/10.1038/ng.2526

[7] Huang, R.Y., Bi, W.L., Griffith, B., Kaufmann, T.J., la Fougère, C., Schmidt, N.O., *et al.* (2019) Imaging and Diagnostic Advances for Intracranial Meningiomas. *Neuro-Oncology*, **21**, i44-i61. https://doi.org/10.1093/neuonc/noy143

[8] Watts, J., Box, G., Galvin, A., Brotchie, P., Trost, N. and Sutherland, T. (2014) Magnetic Resonance Imaging of Meningiomas: A Pictorial Review. *Insights into Imaging*, **5**, 113-122. https://doi.org/10.1007/s13244-013-0302-4

[9] Krishnan, V., Mittal, M.K. and Sinha, M. (2019) Imaging Spectrum of Meningiomas: A Review of Uncommon Imaging Appearances and Their Histopathological and Prognostic Significance. *Polish Journal of Radiology*, **84**, 630-653. https://doi.org/10.5114/pjr.2019.92421

[10] Nauta, H.J., Tucker, W.S., Horsey, W.J., Bilbao, J.M. and Gonsalves, C. (1979) Xanthochromic Cysts Associated with Meningioma. *Journal of Neurology, Neurosurgery & Psychiatry*, **42**, 529-535. https://doi.org/10.1136/jnnp.42.6.529

[11] Rengachary, S., Batnitzky, S., Kepes, J.J., Morantz, R.A., O'Boynick, P. and Watanabe, I. (1979) Cystic Lesions Associated with Intracranial Meningiomas. *Neurosurgery*, **4**, 107-114. https://doi.org/10.1227/00006123-197902000-00001

[12] Pinna, G., Beltramello, A., Buffatti, P., Signorini, G., Colombari, R., Bricolo, A., *et al.* (1986) Cystic Meningiomas—An Update. *Surgical Neurology*, **26**, 441-452. https://doi.org/10.1016/0090-3019(86)90256-9

[13] Fortuna, A., Ferrante, L., Acqui, M., Guglielmi, G. and Mastronardi, L. (1988) Cystic Meningiomas. *Acta Neurochirurgica*, **90**, 23-30. https://doi.org/10.1007/bf01541262

[14] Go, K., Lee, K., Heo, W., Lee, Y.S., Park, Y.S., Kim, S.K., *et al.* (2018) Cystic Meningiomas: Correlation between Radiologic and Histopathologic Features. *Brain Tumor Research and Treatment*, **6**, 13-21. https://doi.org/10.14791/btrt.2018.6.e3

[15] Bitzer, M., Wöckel, L., Morgalla, M., Keller, C., Friese, S., Heiss, E., *et al.* (1997) Peritumoural Brain Oedema in Intracranial Meningiomas: Influence of Tumour Size, Location and Histology. *Acta Neurochirurgica*, **139**, 1136-1142. https://doi.org/10.1007/bf01410973

[16] Bitzer, M., Nägele, T., Geist-Barth, B., Klose, U., Grönewäller, E., Morgalla, M., *et al.* (2000) Role of Hydrodynamic Processes in the Pathogenesis of Peritumoral Brain Edema in Meningiomas. *Journal of Neurosurgery*, **93**, 594-604. https://doi.org/10.3171/jns.2000.93.4.0594

[17] Bitzer, M., Wöckel, L., Luft, A.R., Wakhloo, A.K., Petersen, D., Opitz, H., *et al.* (1997) The Importance of Pial Blood Supply to the Development of Peritumoral Brain Edema in Meningiomas. *Journal of Neurosurgery*, **87**, 368-373. https://doi.org/10.3171/jns.1997.87.3.0368

[18] Bitzer, M., Topka, H., Morgalla, M., Friese, S., Wöckel, L. and Voigt, K. (1998) Tumor-Related Venous Obstruction and Development of Peritumoral Brain Edema in Meningiomas. *Neurosurgery*, **42**, 724-728. https://doi.org/10.1097/00006123-199804000-00026

[19] Yoshioka, H., Hama, S., Taniguchi, E., Sugiyama, K., Arita, K. and Kurisu, K. (1999) Peritumoral Brain Edema Associated with Meningioma: Influence of Vascular Endothelial Growth Factor Expression and Vascular Blood Supply. *Cancer*, **85**, 936-944. https://doi.org/10.1002/(sici)1097-0142(19990215)85:4<936::aid-cncr23>3.0.co;2-j

[20] Reszec, J., Hermanowicz, A., Rutkowski, R., Turek, G., Mariak, Z. and Chyczewski, L. (2015) Expression of MMP-9 and VEGF in Meningiomas and Their Correlation with Peritumoral Brain Edema. *BioMed Research International*, **2015**, Article ID: 646853. https://doi.org/10.1155/2015/646853

[21] Fiani, B., Jarrah, R., Bhandarkar, A.R., De Stefano, F., Amare, A., Aljameey, U.A., *et al.* (2023) Peritumoral Edema in Meningiomas: Pathophysiology, Predictors, and Principles for Treatment. *Clinical and Translational Oncology*, **25**, 866-872. https://doi.org/10.1007/s12094-022-03009-0

[22] Ren, L., Hua, L., Bao, Z., Deng, J., Wang, D., Chen, J., *et al.* (2023) Distinct Clinical Outcome of Microcystic Meningioma as a WHO Grade 1 Meningioma Subtype. *Journal of Neuro-Oncology*, **161**, 193-202. https://doi.org/10.1007/s11060-022-04034-3

[23] Boulagnon-Rombi, C., Fleury, C., Fichel, C., Lefour, S., Marchal Bressenot, A. and Gauchotte, G. (2017) Immunohistochemical Approach to the Differential Diagnosis of Meningiomas and Their Mimics. *Journal of Neuropathology & Experimental Neurology*, **76**, 289-298. https://doi.org/10.1093/jnen/nlx008

[24] Goldbrunner, R., Stavrinou, P., Jenkinson, M.D., Sahm, F., Mawrin, C., Weber, D.C., *et al.* (2021) EANO Guideline on the Diagnosis and Management of Meningiomas. *Neuro-Oncology*, **23**, 1821-1834. https://doi.org/10.1093/neuonc/noab150

[25] Simpson, D. (1957) The Recurrence of Intracranial Meningiomas after Surgical Treatment. *Journal of Neurology, Neurosurgery & Psychiatry*, **20**, 22-39. https://doi.org/10.1136/jnnp.20.1.22

[26] Sughrue, M.E., Kane, A.J., Shangari, G., Rutkowski, M.J., McDermott, M.W., Berger, M.S., *et al.* (2010) The Relevance of Simpson Grade I and II Resection in Modern Neurosurgical Treatment of World Health Organization Grade I Meningiomas. *Journal of Neurosurgery*, **113**, 1029-1035. https://doi.org/10.3171/2010.3.jns091971