Scientific Research Publishing

Case Reports in Clinical Medicine, 2026, 15(11), 516-524
https://www.scirp.org/journal/crcm
ISSN Online: 2325-7083
ISSN Print: 2325-7075

Thrombosed Pseudoaneurysm of the Right Common Carotid Artery in Pre-Rupture: First Case-Report in the Department of Thoracic and Cardiovascular Surgery at Fann National Teaching Hospital in Dakar

Papa Amath Diagne, Abdoul Ahad Mbengue, Mamadou Saliou Diallo, Ndeye Fatou Sow, Thiaw Abdoul Aziz, Mory Camara, Papa Adama Dieng, Ciss Gabriel Amadou

Thoracic and Cardiovascular Surgery Department, National University Hospital Center of Fann, Dakar, Senegal
Email: alahad313@gmail.com

How to cite this paper: Diagne, P.A., Mbengue, A.A., Diallo, M.S., Sow, N.F., Aziz, T.A., Camara, M., Dieng, P.A. and. Amadou, C.G. (2026) Thrombosed Pseudoaneurysm of the Right Common Carotid Artery in Pre-Rupture: First Case-Report in the Department of Thoracic and Cardiovascular Surgery at Fann National Teaching Hospital in Dakar. *Case Reports in Clinical Medicine*, **15**, 516-524.
https://doi.org/10.4236/crcm.2026.1511064

Received: March 2, 2026
Accepted: November 23, 2026
Published: November 26, 2026

Copyright © 2026 by author(s) and Scientific Research Publishing Inc.
This work is licensed under the Creative Commons Attribution International License (CC BY 4.0).
http://creativecommons.org/licenses/by/4.0/

Open Access

Abstract

Background: Extracranial carotid artery pseudoaneurysms are rare, and spontaneous lesions are exceptional. We report a giant thrombosed pseudoaneurysm of the right common carotid artery that required emergency surgery in Dakar; a second pseudoaneurysm was subsequently detected. **Case Presentation**: A 28-year-old man presented with a rapidly enlarging cervical mass, dysphagia, and intermittent disorientation. CTA demonstrated a giant thrombosed pseudoaneurysm of the right common carotid artery with a large cervical hematoma. Emergency open repair with a saphenous vein patch was performed. Recovery was favorable apart from transient hypoglossal nerve dysfunction. At three months, MRA identified a new right internal carotid artery pseudoaneurysm. **Conclusion**: Giant spontaneous carotid pseudoaneurysms are rare and potentially life-threatening. Open reconstruction remains essential when urgent decompression is required or endovascular resources are unavailable. Prolonged imaging surveillance is warranted when multiple lesions occur.

Keywords

Carotid Pseudoaneurysm, Spontaneous, Open Repair, Vascular Surgery, Dakar

1. Introduction

Extracranial carotid artery aneurysms are rare, accounting for 0.4% to 4% of peripheral aneurysms [1]. Pseudoaneurysms constitute an important subgroup and most commonly result from carotid endarterectomy, trauma, infection, or other iatrogenic injuries [2] [3]. Spontaneous lesions, defined by the absence of an identifiable precipitating factor, are uncommon, and their natural history remains poorly characterized [4].

Clinical presentation is variable and may include a cervical mass, compressive symptoms, or neurological manifestations [5]. Doppler ultrasonography is useful for initial assessment, whereas CTA provides detailed morphological evaluation and guides operative planning [6].

Extracranial carotid pseudoaneurysms are clinically important because they may cause thromboembolism, local compression, progressive enlargement, or rupture [1] [7]. Their rarity and heterogeneous presentation preclude a uniform treatment algorithm; management should be individualized according to symptoms, anatomy, etiology, and local expertise [1] [8].

We report a rare case of a giant spontaneous thrombosed pseudoaneurysm of the right common carotid artery in pre-rupture, managed emergently in Dakar, followed by the discovery of a second pseudoaneurysm of the right internal carotid artery. This presentation raises important questions regarding etiology, surveillance, and long-term management.

2. Case Report

A 28-year-old man who worked as a tailor was referred from a health center outside Dakar to the Department of Thoracic and Cardiovascular Surgery at Fann University Hospital for evaluation of a right lateral cervical mass. He reported a five-month history of a painless right cervical swelling that had progressively increased in size without local inflammatory signs, obvious vascular features, or initial compressive symptoms. The mass initially measured 55 × 43 mm and was identified while the patient was receiving treatment for dental caries involving the right mandibular second premolar (tooth 44).

The patient was initially evaluated by an otorhinolaryngologist, who suspected a paravascular soft-tissue mass and referred him to our department. While awaiting elective surgery, he required emergency admission one month and 19 days after the initial consultation because of clinical deterioration during the preceding 48 hours, with dysphagia to solids and intermittent temporospatial disorientation.

On admission, the patient was hemodynamically stable apart from tachycardia at 110 beats/min. Cervical examination revealed a large, pulsatile, expansile right anterolateral mass with a systolic bruit, measuring approximately 15 × 10 cm. The overlying skin was tense but showed no signs of ischemia. Neurological examination revealed intermittent disorientation in time and space, without sensorimotor deficit or clinically evident cranial nerve dysfunction.

CTA of the supra-aortic trunks (**Figure 1**) demonstrated a large recent right

laterocervical hematoma measuring 105.6 × 88.2 × 111.6 mm, related to a 16.2-mm parietal defect of the right common carotid artery. The hematoma compressed the patent right internal jugular vein without a carotid-jugular fistula and displaced the trachea markedly to the left. Both common, internal, and external carotid arteries remained opacified without an endoluminal abnormality. The circle of Willis was complete, with satisfactory opacification of the intracranial arteries. Brain CT showed no evidence of cerebral ischemia. Electrocardiography and transthoracic echocardiography were unremarkable. Serological tests for syphilis and HIV were negative, inflammatory markers were within normal limits, and no systemic infectious focus was identified. These findings supported the initial classification of the lesion as a spontaneous pseudoaneurysm.

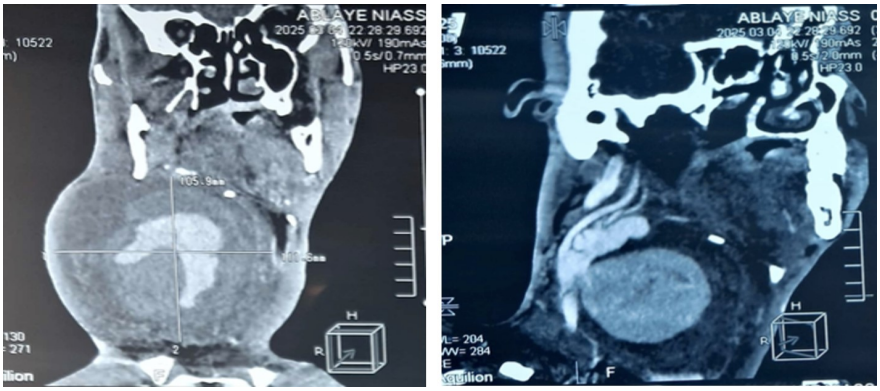

Figure 1. CTA of the supra-aortic trunks showing a thrombosed pseudoaneurysm of the right common carotid artery.

Because of the rapid enlargement of the lesion and the development of compressive symptoms, emergency surgery was indicated. The planned procedure consisted of excision of the pseudoaneurysm and closure of the arterial defect with a saphenous vein patch.

Surgery was performed under general anesthesia after difficult orotracheal intubation. Exposure was obtained through a two-stage right lateral cervicotomy. A 5-cm vertical incision was first made proximal to the mass in the right presternocleidomastoid region and extended to the suprasternal notch, allowing proximal control of the right common carotid artery. A second 10-cm vertical submandibular incision was then made over the mass and connected to the first incision. Distal exposure was difficult. The internal carotid artery was small, thin-walled, and nonpulsatile but was ultimately controlled. The external carotid artery could not initially be isolated because it was incorporated into the pseudoaneurysm sac. The internal jugular vein was identified and preserved. Cranial nerves X and XII could not be clearly identified during dissection.

Exploration revealed a saccular pseudoaneurysm measuring approximately 12 × 8 cm and involving the carotid bifurcation (**Figure 2(A)**). After systemic heparinization with 5,000 IU and proximal and distal vascular control, the sac was opened and thrombotic material and pseudomembranes were removed (**Figure**

2(B)). Samples were sent for bacteriological and mycological examination; all cultures remained negative. A 2-cm anterior arterial defect was identified at the carotid bulb (Figure 3(A)), with satisfactory backflow from the external carotid artery. The defect was closed with a saphenous vein patch using two running 6-0 Prolene sutures (Figure 3(B)). After unclamping, the common, internal, and external carotid arteries were pulsatile. The carotid clamping time was 60 minutes. Systolic blood pressure was maintained at approximately 130 mmHg with norepinephrine support.

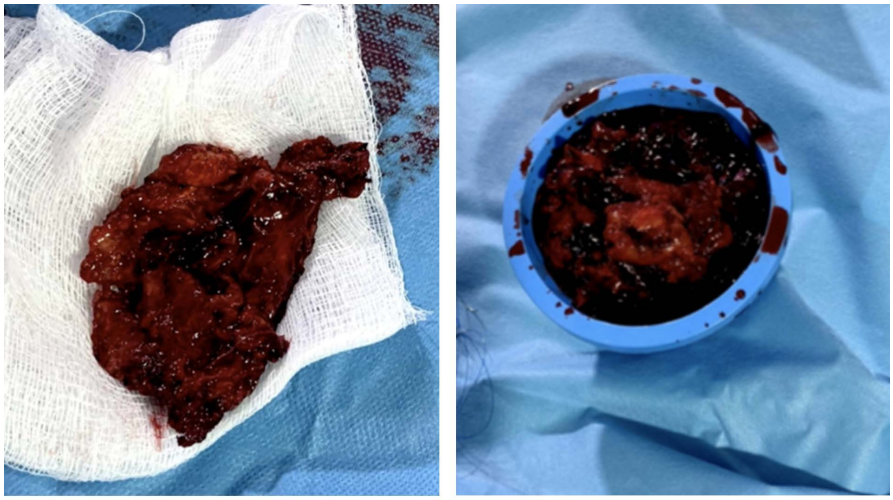

(A) (B)

Figure 2. (A) Pseudoaneurysm sac; (B) Removed thrombotic material.

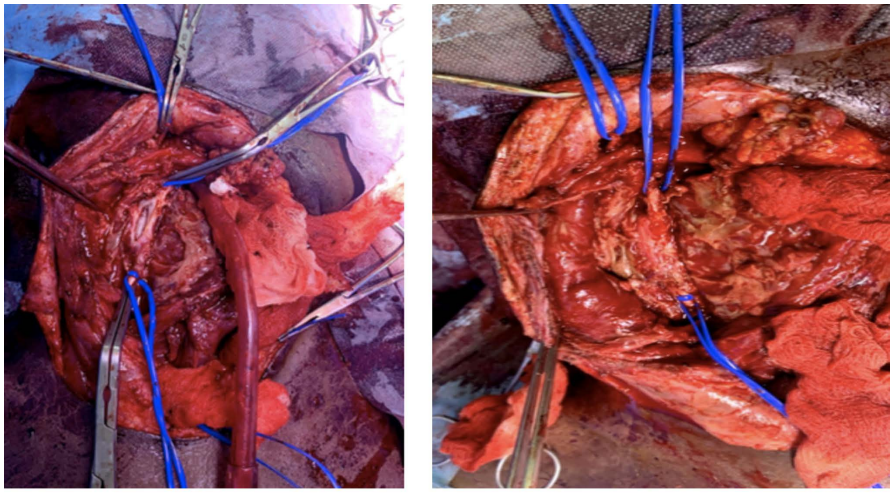

(A) (B)

Figure 3. (A) Arterial defect at the right carotid bulb; (B) Repair with a saphenous vein patch.

The patient was admitted to the intensive care unit for postoperative monitoring. The immediate postoperative course was complicated by ipsilateral tongue weakness, consistent with transient hypoglossal nerve dysfunction. Medical treat-

ment included aspirin (160 mg/day), prophylactic anticoagulation, and broad-spectrum antibiotics for 48 hours while culture results were pending. Postoperative brain CT was normal. Corticosteroid therapy was administered, and the neurological findings subsequently improved. The patient was discharged on postoperative day 5.

At postoperative day 15, the patient was asymptomatic, with near-complete resolution of the neurological findings. Histopathological examination of the sampled arterial wall showed medial hypertrophy without an endothelial abnormality. At three months, the patient remained asymptomatic, and the surgical wound (**Figure 4**) was well healed. Carotid pulses were palpable without a thrill or bruit. Cerebral MRA showed no ischemic or hemorrhagic lesion but identified a right internal carotid artery pseudoaneurysm measuring 21 × 15 mm with a wide thrombosed neck. Retrospective review of the initial CTA did not identify this lesion, suggesting that it had developed during follow-up.



Figure 4. Surgical wound at three-month follow-up.

3. Discussion

A pseudoaneurysm results from disruption of the arterial wall, with blood contained by the surrounding tissues rather than by all native wall layers [7]. This distinguishes it from a true aneurysm, in which the arterial wall remains continuous despite pathological dilatation. Extracranial carotid aneurysms and pseudoaneurysms are uncommon, and spontaneous pseudoaneurysms are particularly rare [1] [4].

Reported etiologies include trauma, previous carotid surgery or other iatrogenic injury, infection, dissection, fibromuscular dysplasia, and connective-tissue disorders [3] [5] [9]. In the absence of an identifiable cause, a lesion may be classified as spontaneous. However, the occurrence of a second pseudoaneurysm in our patient warrants further investigation for an underlying arteriopathy.

Clinical manifestations range from an asymptomatic cervical mass to pulsatility, dysphagia, airway deviation, cranial nerve dysfunction, or cerebral ischemic symptoms [3] [5]. CTA is the principal examination for defining the lesion, thrombus, arterial continuity, adjacent structures, and signs of rupture. Doppler ultrasonography and MRA are useful complementary and surveillance modalities [7] [9].

The pseudoaneurysm in our patient measured approximately 12 cm, which is exceptional compared with the lesions described in most clinical series [3] [5] [10]. Lesions of this size may cause major compressive manifestations and make distal arterial control and identification of the carotid bifurcation and cranial nerves technically difficult.

Table 1. Representative evidence on extracranial carotid artery aneurysms and pseudoaneurysms.

Study	Design and cohort	Management	Key findings and limitations
Welleweerd *et al.*, 2015 [1]	Systematic review; 39 series; 1,239 patients	89% invasive; open repair accounted for 94% of invasive procedures	After surgery: cranial nerve injury 11.8%, 30-day stroke 5.16%, mortality 1.91%. Marked heterogeneity.
Fankhauser *et al.*, 2015 [3]	Retrospective series; 141 aneurysms	Open, endovascular, or nonoperative treatment selected according to presentation	Selected asymptomatic patients were safely observed. Retrospective design and variable follow-up.
Galyfos *et al.*, 2021 [11]	Systematic review; 7 comparative studies; 374 patients	220 open and 81 endovascular repairs	Stroke/TIA: 5.5% vs 1.2%; cranial nerve injury: 14.5% vs 0%. Nonrandomized evidence.
Hoffman *et al.*, 2022 [12]	Systematic review; 28 studies; 906 patients	750 open, 85 endovascular, and 124 conservative treatments	After open repair: cranial nerve injury 9%, stroke 4%, death 2%. Treatment selection depended on anatomy and aneurysm type.
Present case	Case report; one patient with a giant common carotid pseudoaneurysm	Emergency open repair with a saphenous vein patch	Transient hypoglossal dysfunction; second internal carotid pseudoaneurysm detected at three months.

Table 1 summarizes representative evidence on extracranial carotid artery aneurysms and pseudoaneurysms. Available evidence consists mainly of retrospective series and systematic reviews of heterogeneous, nonrandomized studies [1] [3] [11] [12]. Open reconstruction remains the most frequently reported treatment, whereas endovascular repair is increasingly used for selected anatomically suitable lesions [7] [13]. Comparisons should be interpreted cautiously because treatment selection, aneurysm type, anatomy, and follow-up duration differ substantially among studies.

3.1. Therapeutic Implications

Comparative studies have reported similarly low early mortality and cerebrovascular event rates after open and endovascular repair, although open repair carries a higher risk of cranial nerve injury [11]. Endovascular treatment is particularly

attractive for distal lesions or hostile surgical fields when the anatomy is suitable and the necessary devices and expertise are available [6] [13] [14]. In our patient, the giant compressive lesion, threatened rupture, need for hematoma evacuation, and limited device availability favored open repair. Arterial continuity was preserved with a saphenous vein patch, consistent with the principle of reconstruction whenever technically feasible [15].

Cranial nerve injury is a recognized complication of open carotid surgery. Systematic reviews of extracranial carotid aneurysm repair have reported rates of approximately 9% to 14.5%, whereas individual surgical series show substantial variation [11] [12] [15]. Hypoglossal nerve injury is also well recognized after open carotid procedures [16]. The transient hypoglossal nerve dysfunction observed in our patient was therefore consistent with a recognized operative risk and had almost completely resolved during follow-up.

3.2. Follow-Up and Risk of New Lesions

No evidence-based surveillance schedule has been established specifically for extracranial carotid pseudoaneurysms [1] [8] [12]. Follow-up should therefore be individualized and should combine clinical assessment with serial Doppler ultrasonography, CTA, or MRA according to lesion anatomy and renal function. Symptoms, documented enlargement, thromboembolic events, infection, or concerning morphology should prompt multidisciplinary reassessment [4] [8]. The development of a second lesion in our patient supports prolonged, potentially lifelong vascular surveillance.

3.3. Context of Resource-Limited Settings

In resource-limited settings, delayed presentation and restricted access to advanced imaging, endovascular devices, and intensive postoperative care may narrow the available therapeutic options. Open reconstruction therefore remains indispensable when proximal and distal control, cerebral protection, and arterial continuity can be achieved safely.

4. Conclusion

Spontaneous pseudoaneurysm of the common carotid artery is rare and potentially life-threatening. Determining the etiology can be difficult, as illustrated by this case. Because its natural history remains poorly understood, close clinical and imaging surveillance is required. Open reconstruction through a lateral cervicotomy is a feasible option for large, compressive, or threatened lesions when endovascular treatment is unsuitable or unavailable. The occurrence of a second pseudoaneurysm in this patient underscores the need for prolonged surveillance and further etiological investigation.

Ethics and Consent

Written informed consent was obtained from the patient for publication of this

case report and accompanying images. Ethical approval was granted by the institutional review board of Fann National Teaching Hospital, in accordance with local regulations and international ethical standards.

Conflicts of Interest

The authors declare no conflicts of interest regarding the publication of this paper.

References

[1] Welleweerd, J.C., den Ruijter, H.M., Nelissen, B.G.L., Bots, M.L., Kappelle, L.J., Rinkel, G.J.E., *et al.* (2015) Management of Extracranial Carotid Artery Aneurysm: A Systematic Review. *European Journal of Vascular and Endovascular Surgery*, **50**, 141-147. https://doi.org/10.1016/j.ejvs.2015.05.002

[2] Pulli, R., Dorigo, W., Alessi Innocenti, A., Pratesi, G., Fargion, A. and Pratesi, C. (2013) A 20-Year Experience with Surgical Management of True and False Internal Carotid Artery Aneurysms. *European Journal of Vascular and Endovascular Surgery*, **45**, 1-6. https://doi.org/10.1016/j.ejvs.2012.10.011

[3] Fankhauser, G.T., Stone, W.M., Fowl, R.J., O'Donnell, M.E., Bower, T.C., Meyer, F.B., *et al.* (2015) Surgical and Medical Management of Extracranial Carotid Artery Aneurysms. *Journal of Vascular Surgery*, **61**, 389-393. https://doi.org/10.1016/j.jvs.2014.07.092

[4] Pourier, V.E.C., Welleweerd, J.C., Kappelle, L.J., Rinkel, G.J.E., Ruigrok, Y.M., van der Worp, H.B., *et al.* (2018) Experience of a Single Center in the Conservative Approach of 20 Consecutive Cases of Asymptomatic Extracranial Carotid Artery Aneurysms. *European Journal of Neurology*, **25**, 1285-1289. https://doi.org/10.1111/ene.13720

[5] Garg, K., Rockman, C.B., Lee, V., Maldonado, T.S., Jacobowitz, G.R., Adelman, M.A., *et al.* (2012) Presentation and Management of Carotid Artery Aneurysms and Pseudoaneurysms. *Journal of Vascular Surgery*, **55**, 1618-1622. https://doi.org/10.1016/j.jvs.2011.12.054

[6] Welleweerd, J.C., Moll, F.L. and de Borst, G.J. (2012) Technical Options for the Treatment of Extracranial Carotid Aneurysms. *Expert Review of Cardiovascular Therapy*, **10**, 925-931. https://doi.org/10.1586/erc.12.61

[7] Sfyroeras, G.S., Dalainas, I., Giannakopoulos, T.G., Antonopoulos, C.N., Kakisis, J.D. and Liapis, C.D. (2012) True and False Aneurysms of the Carotid Artery: Diagnosis and Management. *Journal of Cardiovascular Surgery* (*Torino*), **53**, 713-723.

[8] de Borst, G.J., van Laarhoven, C.J.H. and Pourier, V.E.C. (2018) Treatment of Extracranial Carotid Artery Aneurysms: What Is Known and What Is Unknown? *EJVES Short Reports*, **38**, 23. https://doi.org/10.1016/j.ejvssr.2017.11.002

[9] van Laarhoven, C.J.H.C.M., Rots, M.L., Pourier, V.E.C., Jorritsma, N.K.N., Leiner, T., Hendrikse, J., *et al.* (2020) Gadolinium Enhancement of the Aneurysm Wall in Extracranial Carotid Artery Aneurysms. *American Journal of Neuroradiology*, **41**, 501-507. https://doi.org/10.3174/ajnr.a6442

[10] El-Sabrout, R. and Cooley, D.A. (2000) Extracranial Carotid Artery Aneurysms: Texas Heart Institute Experience. *Journal of Vascular Surgery*, **31**, 702-712. https://doi.org/10.1067/mva.2000.104101

[11] Galyfos, G., Eleftheriou, M., Theodoropoulos, C., Vouros, D., Georgiou, K., Kimpizi, D., *et al.* (2021) Open versus Endovascular Repair for Extracranial Carotid Aneurysms: A Systematic Review. *Journal of Vascular Surgery*, **74**, 1017-1023.e5.

https://doi.org/10.1016/j.jvs.2021.04.038

[12] Hoffman, M.E., Squiers, J.J., Hamandi, M., Lanfear, A.T., Calligaro, K.D. and Shutze, W.P. (2022) Systematic Review of the Influence of Anatomy and Aneurysm Type on Treatment Choice and Outcomes in Extracranial Carotid Artery Aneurysms. *Annals of Vascular Surgery*, **83**, 349-357. https://doi.org/10.1016/j.avsg.2022.02.006

[13] Giannopoulos, S., Trinidad, E., Aronow, H., Soukas, P. and Armstrong, E.J. (2020) Endovascular Repair of Extracranial Carotid Artery Aneurysms: A Systematic Review. *Vascular and Endovascular Surgery*, **54**, 254-263. https://doi.org/10.1177/1538574419895383

[14] Zhou, W., Lin, P.H., Bush, R.L., Peden, E., Guerrero, M.A., Terramani, T., *et al.* (2006) Carotid Artery Aneurysm: Evolution of Management over Two Decades. *Journal of Vascular Surgery*, **43**, 493-496. https://doi.org/10.1016/j.jvs.2005.11.023

[15] Attigah, N., Külkens, S., Zausig, N., Hansmann, J., Ringleb, P., Hakimi, M., *et al.* (2009) Surgical Therapy of Extracranial Carotid Artery Aneurysms: Long-Term Results over a 24-Year Period. *European Journal of Vascular and Endovascular Surgery*, **37**, 127-133. https://doi.org/10.1016/j.ejvs.2008.10.020

[16] Ballotta, E., Da Giau, G., Renon, L., Narne, S., Saladini, M., Abbruzzese, E., *et al.* (1999) Cranial and Cervical Nerve Injuries after Carotid Endarterectomy: A Prospective Study. *Surgery*, **125**, 85-91. https://doi.org/10.1016/s0039-6060(99)70292-8

List of Abbreviations

ABI	Ankle-Brachial Index
BP	Blood Pressure
CCA	Common Carotid Artery
CTA	Computed Tomography Angiography
CT	Computed Tomography
ECG	Electrocardiogram
ECA	External Carotid Artery
HR	Heart Rate
ICA	Internal Carotid Artery
ICU	Intensive Care Unit
IU	International Units
MRA	Magnetic Resonance Angiography
MRI	Magnetic Resonance Imaging
SAV	Saphenous Vein
X	Vagus nerve
XII	Hypoglossal nerve